



Whole-body MRI including diffusion-weighted imaging compared to CT for staging of malignant melanoma

Firas Mosavi, Gustav Ullenhag & Håkan Ahlström

To cite this article: Firas Mosavi, Gustav Ullenhag & Håkan Ahlström (2013) Whole-body MRI including diffusion-weighted imaging compared to CT for staging of malignant melanoma , Upsala Journal of Medical Sciences, 118:2, 91-97, DOI: [10.3109/03009734.2013.778375](https://doi.org/10.3109/03009734.2013.778375)

To link to this article: <https://doi.org/10.3109/03009734.2013.778375>



© Informa Healthcare



Published online: 10 Apr 2013.



Submit your article to this journal [↗](#)



Article views: 636



View related articles [↗](#)



Citing articles: 11 View citing articles [↗](#)

ORIGINAL ARTICLE

Whole-body MRI including diffusion-weighted imaging compared to CT for staging of malignant melanoma

FIRAS MOSAVI¹, GUSTAV ULLENHAG² & HÅKAN AHLSTRÖM¹

¹Department of Radiology, Uppsala University Hospital, Uppsala, Sweden, and ²Department of Oncology, Uppsala University Hospital, Uppsala, Sweden

Abstract

Background. Whole-body (WB) magnetic resonance imaging (MRI), including diffusion-weighted imaging (DWI), has been increasingly used for the detection of metastatic disease.

Purpose. To assess the value of WB MRI including DWI compared to computed tomography (CT) for staging of malignant melanoma. A second aim was to assess the value of DWI in addition to conventional MR sequences for the detection of lesions.

Material and methods. WB MRI with DWI and CT chest, abdomen, and pelvis were performed in 23 patients with histologically confirmed malignant melanoma. CT before and after the MRI examinations and the clinical follow-up was utilized as the standard of reference.

Results. WB MRI and WB DWI detected 345 and 302 lesions, respectively, compared to 397 lesions with CT. The sensitivity of WB MRI and WB DWI varied considerably in different regions of the body. In the lungs, WB MRI and WB DWI showed 63% and 47% true-positive lesions, respectively. WB MRI and WB DWI detected 56 bone lesions in 12 patients compared to 42 lesions in 8 patients with CT. In addition, WB MRI and WB DWI could detect 68 lesions outside the field of view of CT in six patients.

Conclusion. WB MRI is still not ready to replace CT for staging of malignant melanoma, especially in the thorax region. However, WB MRI is advantageous for detection of bone lesions and lesions outside the investigated volume of the conventional CT. When WB MRI is evaluated, both DWI and conventional MRI sequences must be scrutinized.

Key words: DWI, malignant melanoma, whole-body MRI

Introduction

Whole-body (WB) magnetic resonance imaging (MRI) with diffusion-weighted imaging (DWI) has recently been introduced for the evaluation of multifocal metastases in oncology patients. DWI reflects the movement of water molecules in body tissues due to their random thermal motion. Restriction of water diffusion is inversely associated with the integrity of cell membranes and tissue cellularity (1). DWI provides functional information and can be utilized for the detection and characterization of pathologic processes, not only for acute cerebral infarction, but also for malignant tumors (2).

Recent breakthroughs in DWI technology and especially the development of parallel imaging techniques have facilitated WB diffusion scanning. In 2004, Takahara et al. reported a new WB DWI technique, called ‘diffusion-weighted whole-body imaging with background body signal suppression’ (DWIBS). This method deliberately uses scanning during free breathing to detect lesions in (moving) visceral organs (3). These advances in DWI offer a wide range of potential applications in whole-body oncology imaging. The combination of functional data from DWI and detailed anatomic information given by conventional MR sequences such as T1, T2, and short-tau inversion recovery

(STIR) is believed to provide further improvement in tumor staging.

Imaging plays a critical role in staging of patients with malignant melanoma (4). The prognosis of malignant melanoma is strongly associated with the staging at the time of detection (5). So far, the staging evaluations of metastatic malignant melanoma demand various modalities such as computed tomography (CT), MRI, and positron emission tomography/computed tomography (PET/CT) (4). This approach is excessive and time-consuming. Whole-body, i.e. head to toe, techniques like WB MRI and PET/CT can be optimal procedures to evaluate the tumor spread in a single examination. The benefits of WB MRI, such as its lack of ionizing radiation and whole-body coverage, make it a very attractive candidate for evaluation of distant metastases in cancer patients. To date there are few data assessing WB MRI including DWI for staging of malignant melanoma (6). It is unclear whether DWI can detect all the lesions that are detected in conventional MR sequences.

The main aim of this study was to assess the value of whole-body, i.e. head to toe, MRI including DWI, compared to clinical routine CT for staging of malignant melanoma. A second aim was to assess the value of WB DWI in addition to conventional MR images for the detection of malignant melanoma lesions.

Material and methods

Patients

Between March 2008 and April 2011, 23 patients (14 men and 9 women) with a mean age of 57.6 years (range 18–87 years) were included in this prospective study. Both previously treated and untreated patients were included.

The patients were referred from the oncology department after being informed about the study procedures. The study was approved by the ethics committee. The patients underwent WB MRI including DWI and CT chest, abdomen and pelvis. The interval time between WB MRI and CT was 1–13 days (mean 3.5 days). Follow-up CT examinations were also performed in each patient.

Inclusion criteria consisted of histologically confirmed malignant melanoma with evidence of distant metastases in previous studies. Exclusion criteria were the usual contraindications for performing of MRI such as claustrophobia, metal devices in the body, and pacemaker.

Whole-body MRI

All WB MRI examinations were performed on a 1.5 T system (Gyrosan Intera, Philips, Best, The

Netherlands). The whole body (from head to toe) was covered with an in-built whole-body coil. Seven stations were included, with three sequences in each station: 1) Coronal T1-weighted spin echo (T1W) sequence with breath-holding in abdomen and thorax; 2) Coronal fat-suppressed T2-weighted STIR (T2W-STIR) sequence with respiratory triggering in thorax and abdomen; and 3) DW imaging performed in transversal plane during free breathing using b-value of 1000 and 0 mm²/s. High-resolution 3D-maximum intensity projection images (MIP) of the whole body were reconstructed from the transversal diffusion images.

In addition to the sequences above, transversal T2-weighted turbo spin echo (T2W-TSE) and T1-weighted gradient echo (T1W-GE) in- and out-of-phase sequences of the abdomen and thorax were performed for further evaluation of suspected lesions. The investigations were performed without intravenous contrast agent administration.

Total examination time was approximately 50 minutes. The imaging parameters are summarized in Table I.

CT chest, abdomen, and pelvis

The CT examinations were performed with conventional spiral technology and 3 mm slice thickness from the root of the neck to the upper part of the thighs as part of routine clinical care by different scanners. Except for one patient who was allergic to intravenous contrast, the other patients underwent examination after injection of intravenous contrast in chest, abdomen, and pelvis.

Evaluation of MR and CT imaging

WB DWI and WB MRI were first evaluated by two experienced radiologists in consensus, blinded from the CT examinations. Then, CT images (chest, abdomen, and pelvis) were evaluated by one of the radiologists with access to the clinical report.

Finally, the MR and CT images were reviewed together on a lesion-by-lesion basis, and correlating and non-correlating lesions between the modalities were noted. Additional lesions in MRI outside the investigated CT volume were also reported. These comparative analyses were performed by the two radiologists in consensus.

The WB MRI examinations were analyzed by two different approaches. In the first approach, called WB DWI, diffusion-weighted images were evaluated starting with review of maximum intensity projection (MIP) images to get an overview of suspected lesions. The lesion was then verified by analyzing transversal

Table 1. MR imaging sequence protocol.

Imaging parameters	T1W imaging	T2-STIR imaging	DWI
Sequence type	Turbo spin echo	Turbo spin echo	Echo planar imaging
TR/TE/TI	324/17.5/0	2758/64/165	3257/70/180
Slice thickness/gap (mm)	6/1	6/1	6/0
No. of slices per station	33–45	33–45	44
Field of view (mm)	265 × 530	265 × 530	374 × 530
Matrix	208 × 287	120 × 336	112 × 74
Bandwidth/pixel (hertz)	485.6	496	20.4
Scan/station (s)	60	50	142
No. of signal averages	1	2	2
B-value s/mm ²			0 and 1000

TR = repetition time; TE = echo time; TI = time inversion.

WB DWIs using b-value of 1000 mm²/s. A b-value of 0 mm²/s was also used to rule out T2-shine-through effect and to acquire anatomical details. In the DWI, a lesion was defined as a focal area with equal or higher signal intensity than the organ with highest signal intensity in each investigated region, e.g. the brain in the neck region and the bone-marrow in other regions (7). Positive findings on DWIs had to be confirmed on whole-body T1- and T2-STIR-weighted imaging.

In the second approach, called WB MRI, T1-weighted and T2-STIR images were evaluated together with DWI.

The presence of malignancy on CT and MRI was based on conventional morphological and contrast enhancement criteria. A lymph node was considered as metastasis if its short axis diameter was greater than 1 cm and its shape was round (8).

The long axis diameter of each lesion, except for lymph nodes, was measured on CT and conventional MR images. The lesions were sorted into three groups: 1) 0.5 cm and less; 2) 0.6–0.9 cm; and 3) 1 cm and above.

Standard of reference: Each patient underwent several CT examinations both before and after the MRI examinations, and these examinations were used as the standard of reference.

Statistics

Pathological findings in each patient were analyzed separately in WB MRI and WB DWI compared to the standard of reference. Patient- and lesion-based analyses were performed, and the results were reported as true-positive, false-positive, and false-negative; true-negative findings could not be analyzed due to the constraining definition of positive lesions in this study.

Results

CT examinations were able to identify 397 lesions, whereas WB MRI and WB DWI detected 345 and 302 lesions, respectively (Table II). In patient-based analysis, lung lesions were found in 13/16 (81%) patients with WB MRI and in 11/16 (68%) patients with WB DWI. In liver, WB MRI and WB DWI detected lesions in 12/12 (100%) patients (Table III). Two patients showed lesions in the spleen which could not be detected with WB DWI but could be identified both with CT and conventional MRI.

In lesion-based analysis, WB MRI and WB DWI showed 63% and 47% true-positive findings in lungs, respectively (Figure 1). WB MRI and WB DWI showed 90% and 81% true-positive lesions in the liver (Table III). An equal number of abdominal and axillary lymph nodes and subcutaneous metastases were detected with WB MRI, WB MRI, and CT (Table III). WB DWI showed similar results as WB MRI in detection of lesions outside of the CT field of view.

WB MRI and WB DWI detected a significantly higher number of bone lesions compared to CT. WB MRI and WB DWI detected equally 56 bone lesions in 12 patients, while CT showed 42 bone lesions in 8 patients (Figure 2).

CT and WB MRI detected 14 versus 4 lesions with size 0.5 cm and less, 84 versus 38 lesions with size 0.6–0.9 cm, and 299 versus 303 with size 1 cm and above.

In addition, WB MRI and WB DWI could both detect 68 lesions outside the field of view of CT in six patients as follows: 5 brain metastases in two patients, 27 bone lesions in six patients, 19 subcutaneous lesions in four patients, 16 lymph node metastases in three patients, and 1 lesion in the parotid glands in one patient (Figure 3).

Table 2. Assessment of malignant melanoma metastases in 23 patients with DWI, all WB MR sequences,^a and CT thorax, abdomen and pelvis.

Site of metastasis	DWI		All MR sequences ^a		CT	
	Lesions	Patients	Lesions	Patients	Lesions	Patients
Liver	53	12	59	12	65	12
Spleen	0	0	11	2	11	2
Lung	60	11	81	13	127	16
Bone	56	12	56	12	42	8
Lymph nodes in abdomen	71	14	71	14	71	14
Lymph nodes in thorax ^b	18	10	23	12	37	13
Axillary lymph nodes	11	5	11	5	11	5
Subcutaneous metastases	33	6	33	6	33	6

^aT1W, T2-STIR, and DWI.^bDefined as mediastinum and hilar regions.

Discussion

Our prospective study shows that the sensitivity of WB MRI and WB DWI varies considerably in different regions of the body. WB MRI and WB DWI detected fewer lesions in the thorax region, i.e. lung lesions and enlarged lymph nodes in the mediastinum and hila, compared to CT. The difficulties in evaluation of thorax by WB MRI may be due to the presence of cardiac and respiratory motion artifacts in this region. Respiratory-triggered or breath-hold techniques may improve the results of WB DWI in the thorax region (9).

WB MRI and WB DWI proved to have a potential in the detection of metastases in the abdominal region and especially in the skeleton. Bone lesions were excluded from the analysis in Table III because the results would falsely show a high rate of false-

positive findings in MRI compared to CT images. MRI is known to have a very high sensitivity and specificity in detection of bone metastases (10-13).

Müller-Horvat et al. showed the superiority of WB MRI, without DWI, over CT (except for lung lesions) in detection of metastases from malignant melanoma. MRI could change the treatment decision in 24% of patients (14). Furthermore, MRI was found to detect more lesions in liver, spleen, subcutaneous tissue, and muscle, while in our study we had rather similar results from CT and WB MRI including DWI in these regions. The reason for the better results in that study compared to our study is probably the use of intravenous MR contrast agent. Liver-specific MR contrast is especially important for detection of liver metastases.

Laurent et al. compared WB MRI, including DWI and PET/CT, showing higher sensitivity and

Table 3. Lesion- and patient-based analysis of all MRI sequences and DWI in evaluation of metastases from malignant melanoma, compared to CT images.

Site of metastases	Lesion-based analysis						Patient-based analysis					
	DWI			All MRI sequences ^a			DWI			All MRI sequences ^a		
	TP	FP	FN	TP	FP	FN	TP	FP	FN	TP	FP	FN
Liver	81%	0	19%	90%	0	10%	100%	0	0	100%	0	0
Spleen	0	0	100%	100%	0	0	0	0	100%	100%	0	0
Lung	47%	0	53%	63%	0	37%	68%	0	32%	81%	0	19%
Lymph nodes in thorax	48%	0	52%	62%	0	38%	77%	0	23%	92%	0	8%
Lymph nodes in abdomen	100%	0	0	100%	0	0	100%	0	0	100%	0	0
Axillary lymph nodes	100%	0	0	100%	0	0	100%	0	0	100%	0	0
Subcutaneous metastases	100%	0	0	100%	0	0	100%	0	0	100%	0	0

^aT1W, T2-STIR, and DWI.

DWI = Diffusion-weighted imaging; TP = True-positive; FP = False-positive; FN = False-negative.

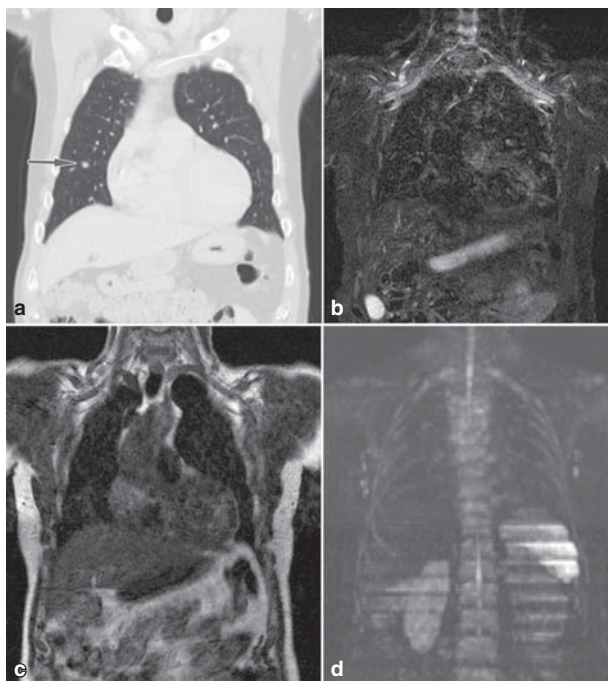


Figure 1. A 66-year-old man with multiple malignant melanoma metastases. The CT image, coronal reconstruction, showed a lesion in the right lung (arrow) measuring approximately 7 mm in longest diameter (a). The lesion was not detectable on STIR and T1 images (b and c). The lesion could not be detected on coronal maximum intensity projection (MIP) DWI image (d). The lesion was not detected on axial DWI (not shown).

specificity for WB MRI in detection of metastases from malignant melanoma (6). In that study, DWI enabled the detection of an additional 20% lesions compared to conventional MRI protocol and also proved to be the most accurate sequence for detection of metastases in the liver, bone, subcutaneous, and intraperitoneal region. The better results of DWI in that study compared to our study can partly depend on the different diffusion factors of $b = 0$ and 600 compared to $b = 0$ and 1000 in our study. Another difference in DWI was that in the Laurent *et al.* study phased-array surface coil was used with Siemens equipment, while we used Philips equipment with in-built whole-body coil and the DWIBS technique.

We used CT thorax, abdomen, and pelvis as the comparison modality since PET/CT has a limited availability. CT is at present the most widely applied imaging modality in tumor staging, follow-up, and evaluation of therapeutic response in patients with malignant melanoma (15). However, malignant melanoma metastases can be located anywhere in the body. We found several lesions outside the CT field of view which adds further support for a whole-body (from head to toe) approach.

WB MRI generates a lot of data and images, and a simplified approach for analysis is needed. Therefore, we wanted to assess whether all lesions were seen in the DWI MIP images. DWI using MIP images can highlight the metastatic lesions, which facilitates the overall evaluation of tumor spread (Figure 3). Each lesion should then be verified with axial DWI and conventional MR images. According to our study results, the evaluation of WB MRI must also include the scrutiny of conventional MRI such as T1 and STIR images for detection of additional lesions. It must be emphasized that our whole-body protocol, due to time limitation, differs considerably from a dedicated regional MRI examination which has significantly higher accuracy in the detection of lesions. However, there was no difference between WB MRI and CT in grade of staging of malignant melanoma.

There were some limitations in our study. Firstly, we could not verify the pathologic findings by biopsy for practical and ethical reasons. Secondly, we did not evaluate DWI completely separated from other MR sequences. We chose this way of interpretation since, apart from malignant tumors, artifacts and a number of benign lesions and normal anatomical structures like spleen and prostate also show high signal intensity

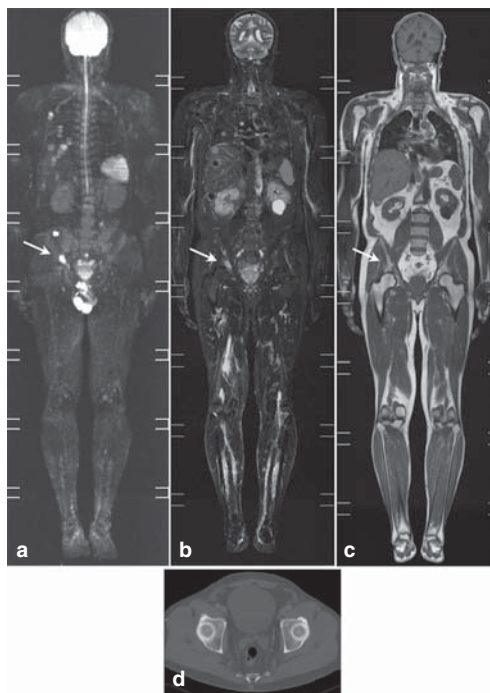


Figure 2. A 64-year-old man with malignant melanoma and multiple metastases. A bone lesion (arrow) measuring approximately 15 mm in longest diameter was detected on the right acetabulum on maximum intensity projection (MIP) image of DWI (a); coronal T2-STIR image (b) and coronal T1W image (c); The lesion was not detectable on CT (d).

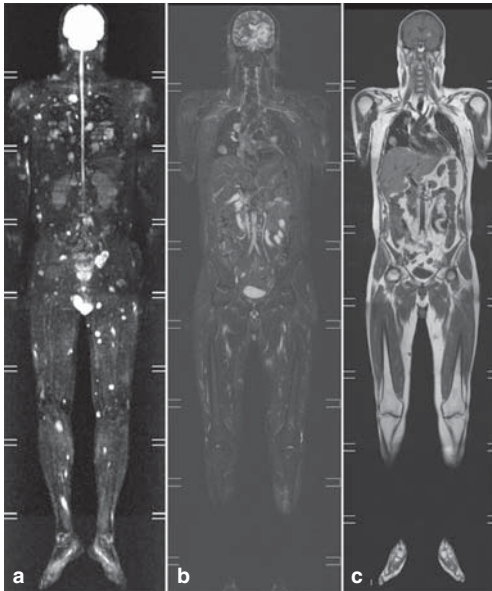


Figure 3. A 41-year-old man with malignant melanoma and widespread metastases including the brain. WB MRI imaging shows multiple lesions outside the field of view of CT thorax and abdomen. (a) A maximum intensity projection (MIP) image of DWI shows the disease distribution in a valuable overview of the entire body; (b) coronal T2-STIR and (c) coronal T1W sequence, respectively, show further anatomical details of metastatic lesions.

in the visual evaluation of DWI, which can be misinterpreted as malignant processes. Furthermore, DWI is mainly related to T2-weighted imaging, and a high diffusion signal can alternatively depend on prolonged T2-relaxation time, known as T2-shine-through effect, seen in e.g. lesions with high fluid content. Other studies suggest interpretation of DWI in correlation to other MR sequences to reduce these possible errors (16,17). Thirdly, the small patient cohort reduces the relevance of statistical analysis, and therefore further studies with larger samples of patients are needed. Furthermore, both treated and non-treated patients were included, and this can potentially lead to difficulties in the evaluation of DWI, as any sort of therapeutic process that causes necrotic cell death will result in decreased diffusion signal using high b-values (18).

In summary, WB MRI including DWI as a non-ionizing whole-body covering technique may potentially be useful in the evaluation of metastatic malignant melanoma. When WB MRI is evaluated, both DWI and conventional MRI sequences must be scrutinized. However, our study results suggest that this imaging modality is still not ready to completely replace CT for evaluation of malignant melanoma metastases. Further protocol optimization of WB MRI including DWI is required before implementation of these methods may be considered.

Declaration of interest: The authors report no conflicts of interest. The authors alone are responsible for the content and writing of the paper. The study has been supported by the Research Foundation Stiftelsen Onkologiska Kliniken in Uppsala Forskningsfond, and also by grants to Professor H. Ahlström from the Swedish Cancer Society, Uppsala University and Hospital (ALF).

References

1. Vilanova JC, Barceló J. Diffusion-weighted whole-body MR screening. *Eur J Radiol.* 2008;67:440–7.
2. Kwee TC, Takahara T, Ochiai R, Nievelstein RA, Luijten PR. Diffusion-weighted whole-body imaging with background body signal suppression (DWIBS): features and potential application in oncology. *Eur Radiol.* 2008;18:1937–52.
3. Takahara T, Imai Y, Yamashita T, Yasuda S, Nasu S, Van Cauteren M. Diffusion weighted whole body imaging with background body signal suppression (DWIBS): technical improvement using free breathing, STIR and high resolution 3D display. *Radiat Med.* 2004;22:275–82.
4. Mohr P, Eggermont AM, Hauschild A, Buzaid A. Staging of cutaneous melanoma. *Ann Oncol.* 2009;20:vi14–21.
5. Balch CM, Soong SJ, Gershenwald JE, Thompson JF, Reintgen DS, Cascinelli N, et al. Prognostic factors analysis of 17,600 melanoma patients: validation of the American Joint Committee on Cancer melanoma staging system. *J Clin Oncol.* 2001;19:3622–34.
6. Laurent V, Trausch G, Bruot O, Olivier P, Felblinger J, Régent D. Comparative study of two whole-body imaging techniques in the case of melanoma metastases: advantages of multi-contrast MRI examination including a diffusion-weighted sequence in comparison with PET/CT. *Eur J Radiol.* 2010;75:376–83.
7. Abdulqadhr G, Molin D, Åström G, Suurkula M, Johansson L, Hagberg H, et al. Whole-body diffusion-weighted imaging compared with FDG-PET/CT in staging of lymphoma patients. *Acta Radiol.* 2011;52:173–80.
8. Eisenhauer EA, Therasse P, Bogaerts J, Schwartz LH, Sargent D, Ford R, et al. New response evaluation criteria in solid tumours: revised RECIST guideline (version 1.1). *Eur J Cancer.* 2009;45:228–47.
9. Kartalis N, Loizou L, Edsborg N, Segersvärd R, Albiin N. Optimising diffusion-weighted MR imaging for demonstrating pancreatic cancer: a comparison of respiratory-triggered, free breathing and breath-hold techniques. *Eur Radiol.* 2012;22:2186–92.
10. Pfannenbergs C, Aschoff P, Schanz S, Eschmann SM, Plathow C, Eigentler TK, et al. Prospective comparison of 18F-fluorodeoxyglucose positron emission tomography/computed tomography and whole-body magnetic resonance imaging in staging of advanced malignant melanoma. *Eur J Cancer.* 2007;43:557–64.
11. Schmidt GP, Schoenberg SO, Schmid R, Stahl R, Tiling R, Becker CR, et al. Screening for bone metastases: whole-body MRI using a 32-channel system versus dual-modality PET/CT. *Eur Radiol.* 2007;17:939–49.
12. Lecouvet FE, Geukens D, Stainier A, Jamar F, d'Othée BJ, Therasse P, et al. Magnetic resonance imaging of the axial skeleton for detecting bone metastases in patients with high risk prostate cancer: diagnostic and cost-effectiveness and comparison with current detection strategies. *J Clin Oncol.* 2007;25:3281–7.

13. Takenaka D, Ohno Y, Matsumoto K, Aoyama N, Onishi Y, Koyama H, et al. Detection of bone metastases in non-small cell lung cancer patients: comparison of whole-body diffusion-weighted imaging (DWI), whole-body MR imaging without and with DWI, whole-body FDG-PET/CT, and bone scintigraphy. *J Magn Reson Imaging*. 2009;30:298–308.
14. Müller-Horvat C, Radny P, Eigentler TK, Schäfer J, Pfannenbergl C, Horger M, et al. Prospective comparison of the impact on treatment decisions of whole-body magnetic resonance imaging and computed tomography in patients with metastatic malignant melanoma. *Eur J Cancer*. 2006;42:342–50.
15. Patnana M, Bronstein Y, Szklaruk J, Bedi DG, Hwu WJ, Gershenwald JE, et al. Multimethod imaging, staging, and spectrum of manifestations of metastatic melanoma. *Clin Radiol*. 2011;66:224–36.
16. Lambregts DM, Maas M, Cappendijk VC, Prompers LM, Mottaghy FM, Beets GL, et al. Whole-body diffusion-weighted magnetic resonance imaging: current evidence in oncology and potential role in colorectal cancer staging. *Eur J Cancer*. 2011; 47:2107–16.
17. Koh DM, Takahara T, Imai Y, Collins DJ. Practical aspects of assessing tumors using clinical diffusion-weighted imaging in the body. *Magn Reson Med Sci*. 2007;6:211–24.
18. Padhani AR, Koh DM, Collins DJ. Whole-body diffusion-weighted MR imaging in cancer: current status and research directions. *Radiology*. 2011;261:700–18.