

Synovial Sarcoma with Massive Ossification – A Case Report

Seigo Hara, Masahito Hatori, Masami Hosaka, Tetsuro Komatsu,
Takashi Tsuchiya, Noriko Kimura

Department of orthopaedic surgery, Tohoku Rosai Hospital, Sendai, Japan, Department of orthopaedic surgery, Tohoku University School of Medicine, Sendai, Japan, Department of orthopaedic surgery, Yamagata University School of Medicine, Yamagata, Japan, Department of pathology, Tohoku Rosai Hospital, Sendai, Japan

ABSTRACT

Synovial sarcoma with extensive osteoid production is rare. We report a case of synovial sarcoma of monophasic type with massive ossification. The diagnosis was confirmed by reverse-transcriptase polymerase chain reaction (RT-PCR). The patient was an 81-year-old woman with recurrent synovial sarcoma in her right knee. The tumor was primarily excised in 1989. It recurred and was removed again in 1996. However, in 1999 a painful mass appeared in the same site. Preoperative plain radiography and computed tomography revealed a 5x5 cm soft tissue mass with extensive ossification in the medial side of the right knee joint. The tumor was widely excised in 2000. Soft X-ray examination revealed a trabecular pattern of ossification in the excised tumor. Microscopically the tumor was composed of hypercellular spindle cells with fascicular arrangement with prominent ossification but no epithelial component. The tumor cells were positive for vimentin and focally positive for cytokeratin. The tumor expressed a sequence of SYT-SSX1 fusion gene transcript demonstrated by RT-PCR. Twelve years long survival of the present case without metastasis in spite of repeated recurrence suggests a better prognosis of synovial sarcomas with ossification.

INTRODUCTION

Synovial sarcoma, which occurs most prevalently in adolescents and young adults are usually at the extremities in the vicinity of the large joints (1). Stippled calcifications detectable radiologically and seen as scattered spotty calcifications microscopically are a well-known feature of synovial sarcoma occurring in approximately 30% of the all studied cases (2). However, synovial sarcoma with extensive calcification and osteoid production seems to be extremely rare (3). We report a

Received 21 March 2003

Accepted 9 May 2003

Key words: Synovial sarcoma, monophasic fibrous type, SYT-SSX fusion transcript, prognosis.

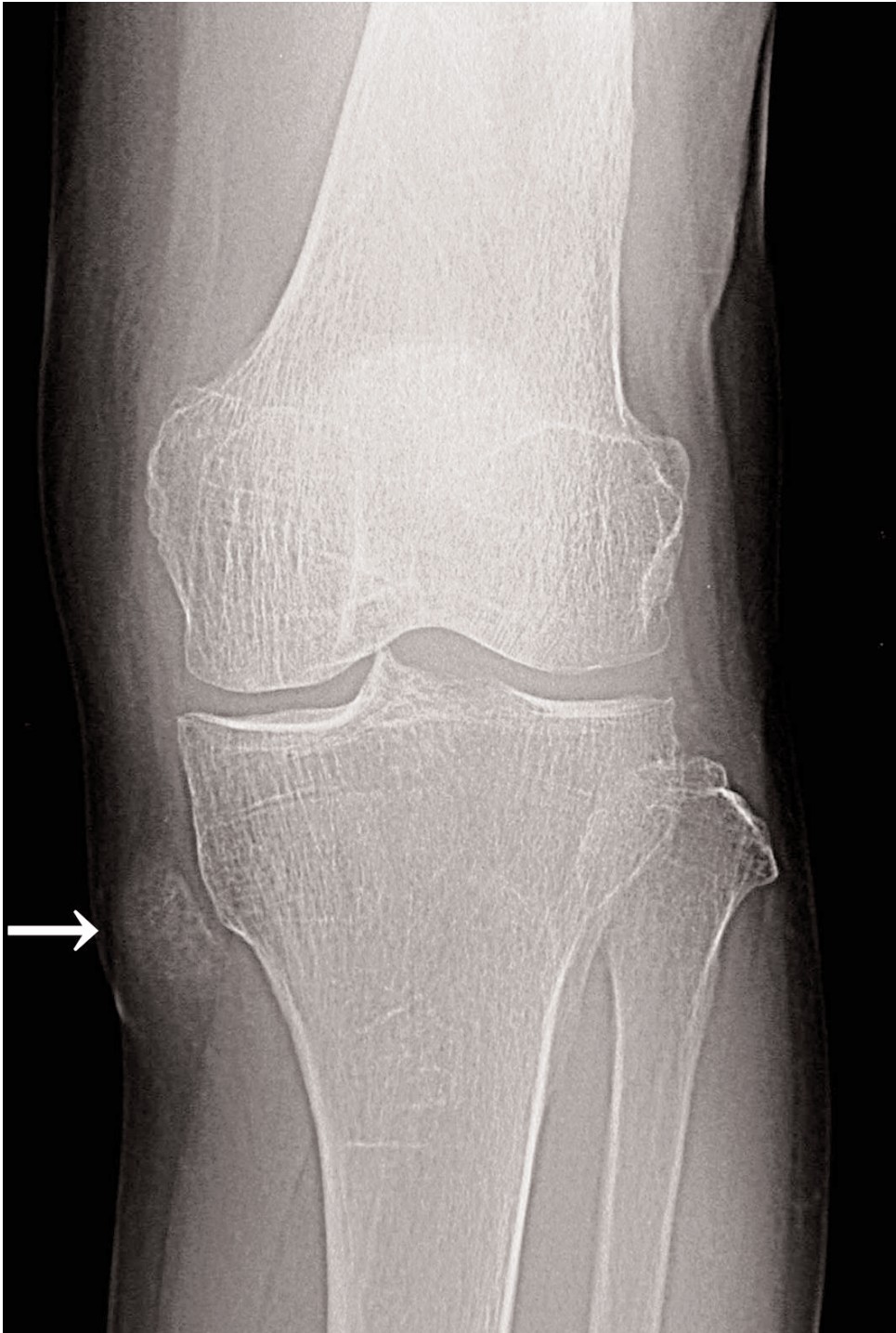

Fig. 1. Plain radiogram showing calcified shadow (arrow) in the medial side of the right knee joint.

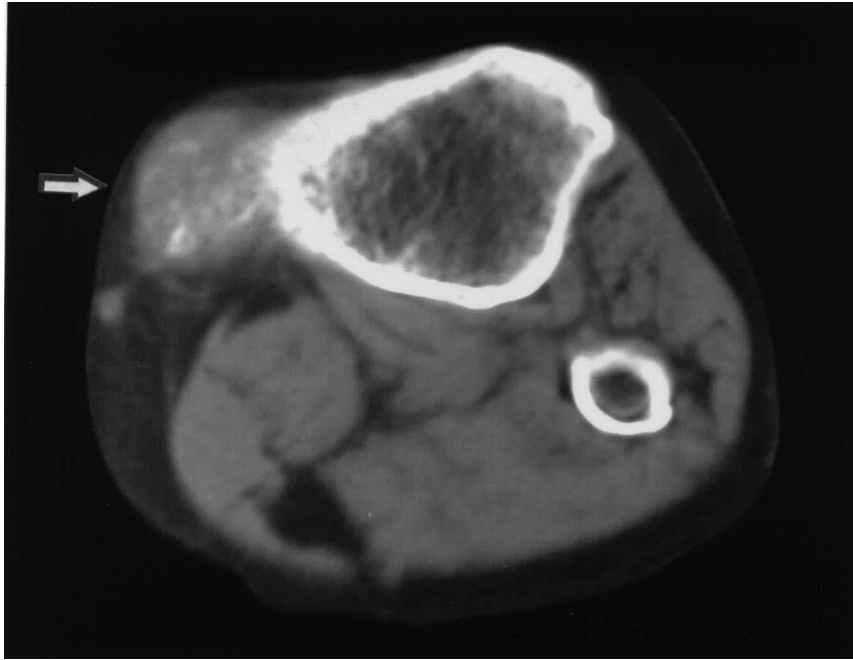


Fig. 2. Computed tomogram showing calcification (arrow) inside the tumor.

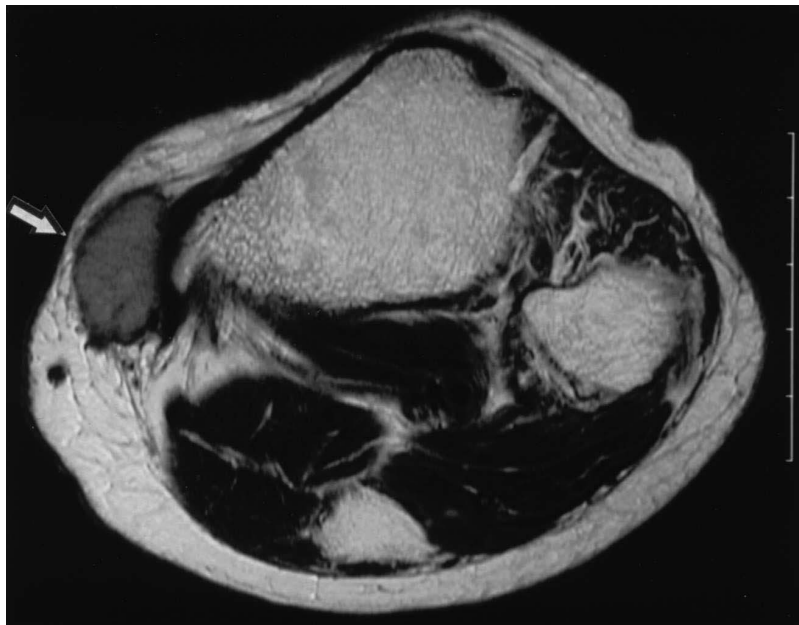


Fig. 3. T2 weighted magnetic resonance imaging showing slightly high intensities of the tumor (arrow) and no involvement of the intramedullary portion of the tibia.

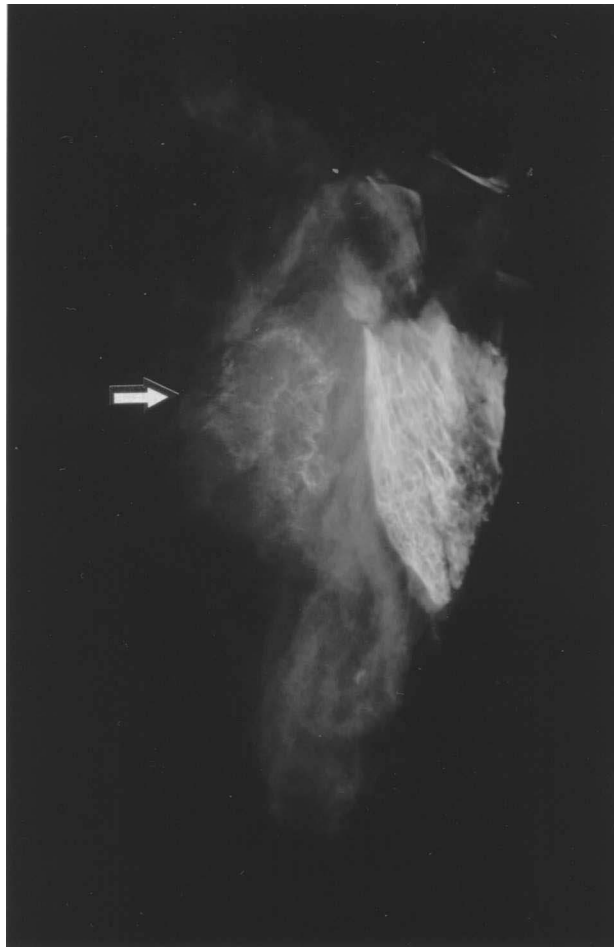

Fig. 4. Microphotograph of the excised tumor showing hypercellular spindle cell proliferation with a fascicular arrangement. The tumor cells were uniform in appearance with small amounts of indistinct cytoplasm and oval dark-staining nuclei.

case of synovial Å sarcoma with extensive ossification, the diagnosis of which was confirmed by reverse-transcriptase polymerase chain reaction (RT-PCR).

Case

In 1989 an 81-year-old woman had a painful mass in her right knee removed. The tumor recurred and was excised again in 1996. However, the painful mass appeared in the same site in 1999. On initial examination a 5x5 cm elastic hard mass was palpated in the medial side of the right knee joint. Plain radiograms revealed calcified shadows (Fig.1). Computed tomography(CT) showed calcification in the tumor (Fig. 2). Magnetic resonance imaging(MRI) revealed a mass with iso-signal intensities on T1 weighted images, slightly high intensities on T2 weighted images (Fig. 3)

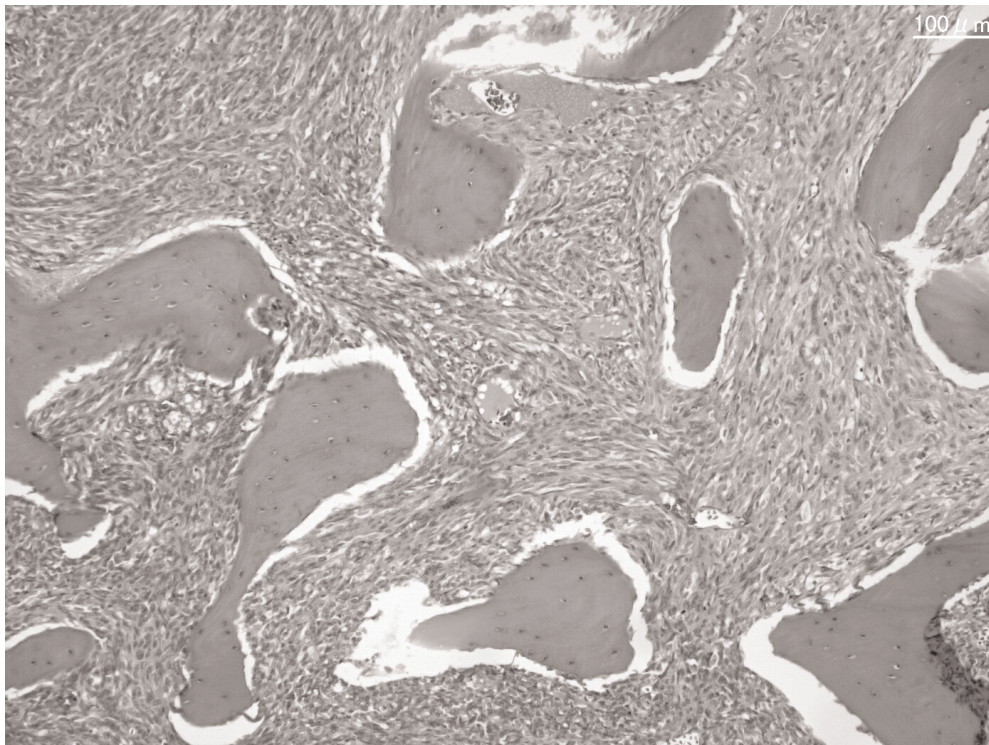


Fig. 5. Microphotograph of the tumor showing pronounced ossification with irregular shaped bone trabeculae without rims of osteoblasts in both peripheral and central regions of the tumor.

and irregular enhancement after an intravenous gadolinium (Gd) compound injection. No signal change was seen in the bone marrow. In July 2000, a wide excision with gastrocnemius flap and skin transplantation was performed. Macroscopically the solid tumor was well encapsulated, yellowish white in color, and had massive ossification. The tibia was not involved. Soft X-ray revealed a trabecular pattern of ossification in the tumor.

The histology of the tumors excised in 1996 and 2000 had a similar pattern. The tumors were composed of spindle cells with fascicular arrangement. The tumor cells were uniform in appearance with small amounts of indistinct cytoplasm and oval dark-staining nuclei (Fig. 4). The mitotic figures were five percent higher in the peripheral region of the tumor. Ossification was pronounced and irregular shaped bone trabeculae without rims of osteoblasts were observed in both the peripheral and central regions of the tumor (Fig. 5). Epithelial component were not seen. The tumor cells were focally positive for cytokeratin and epithelia membrane antigen by immunohistochemical study. Synovial sarcoma of monophasic fibrous type with osseous metaplasia was strongly suspected. In order to confirm the diagnosis, RT-PCR method was performed by using RNA obtained from frozen tissue sections of

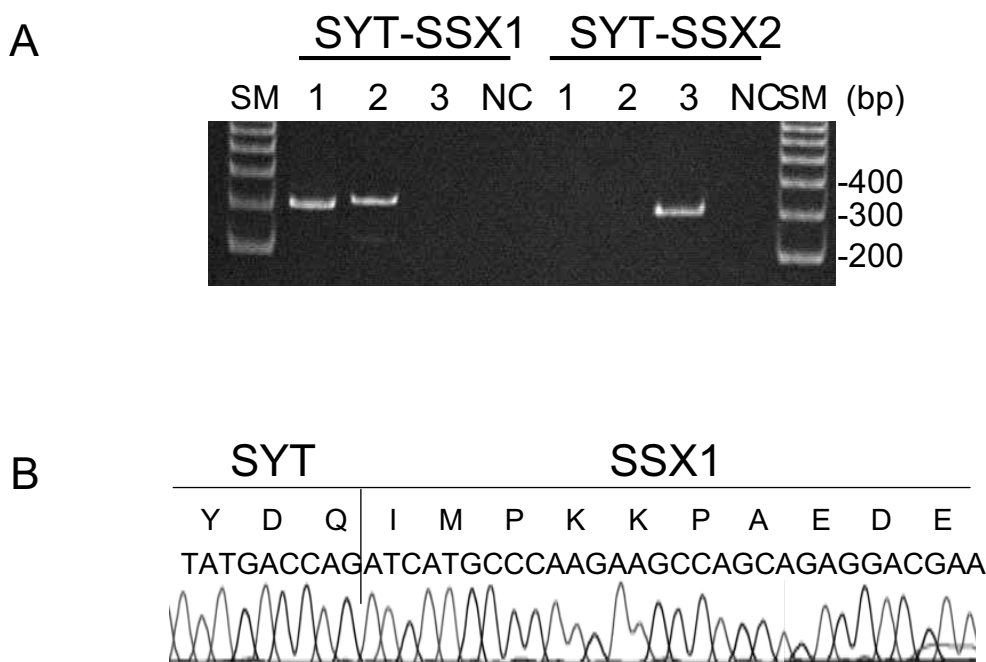


Fig. 6A. RT-PCR detection of transcriptions of SYT-SSX1 and SYT-SSX2 fusion genes. 1; the present case (331bp), 2; another case with a rare variant SYT-SSX1 fusion gene (343bp), 3; a third case with typical SYT-SSX2 fusion gene (331bp). SM; size marker (100bp DNA ladder), NC; negative control.
Fig. 6B. Sequences of transcriptions of SYT-SSX1 of the present case.

the tumor(4). The SYT-SSX1 fusion gene transcript was amplified in the present case, but not SYT-SSX2 (Fig. 6A). Sequences of the transcript had a typical pattern for SYT-SSX1 fusion gene (Fig. 6B)(5).

Taken together, these results verified the diagnosis of the present tumor as synovial sarcoma of monophasic type with unusual massive ossification. The patient has been free from recurrence for two and half years after the last surgery.

DISCUSSION

It is noteworthy that the present synovial sarcoma demonstrated massive ossification and calcification. The tumor was composed of fascicular growth pattern of spindle cells and irregular shaped bone trabeculae without rims of osteoblasts. The tumor cells were partially positive for cytokeratin, the findings of which, except for massive ossification, are well in accordance with the definition of monophasic type of synovial sarcoma based on WHO classification. It is well known that the diagnosis of the monophasic type of synovial sarcoma is sometimes very difficult (6). The differential diagnoses are as follows; extraskeletal osteosarcoma, extraskeletal chondrosarcoma, malignant fibrous histiocytoma of soft tissue or myositis ossifi-

cans (7,8,9,10) because of the presence of ossification and calcification. Particularly extraskeletal osteosarcoma had to be ruled out because of a ribbon-like pattern of the trabeculae in the present tumor. In order to confirm the diagnosis of synovial sarcoma, we analyzed SYT-SSX fusion transcript. The SYT-SSX1 fusion fashion was typical in the present case. Unusual massive ossification of this tumor might be correlated with additional alterations of other genes. Kawai et al. reported that synovial sarcomas with SYT-SSX2 had significantly better metastasis-free survival than those with SYT-SSX1 and that histologic subtype alone was not prognostically important (4).

Six synovial sarcomas associated with ossification (SSAO), including the present case have been reported so far (3,11). The ratio of sex, anatomical location and clinical complaint are almost the same between SSAO and other synovial sarcomas (1). However, the prognosis for synovial sarcomas varies, tumors without ossification have a reported 10-year survival rate ranging from 20%(12) to 38%(13). Milchgrub et al. reported that three out of four cases with massive ossification survived after surgery (3). Another case with extensive ossification reported by Winnepeninckx et al. also had a long clinical course (11). The present case has survived 12 years without metastasis in spite of repeated recurrences, which suggests a better prognosis of synovial sarcomas with ossification.

REFERENCES

1. Weiss SW, Goldblum JR (2001). Synovial sarcoma. In :Weiss SW, Goldblum JR, editors. Enzinger and Weiss's soft tissue tumors. St. Louis, London, Philadelphia, Sydney, Toronto: Mosby: 1483–1509.
2. Varela-Duran J, Enzinger FM (1982). Calcifying synovial sarcoma. *Cancer* 50 :345–352.
3. Milchgrub S, Ghandur-Mnaymeh L, Dorfman HD, Albores-Saavedra J (1993). Synovial sarcoma with extensive osteoid and bone formation. *Am J Pathol* 17 :357–363.
4. Kawai A, Woodruff J, Healey JH, Brennan MF, Antonescu CR, Ladanyi M (1998). SYT-SSX gene fusion as a determinant of morphology and prognosis in synovial sarcoma. *N Eng J Med* 15:153–160.
5. Crew AJ, Clark J, Fisher C, Gill S, Grimer R, Chand A, Shipley J, Gusterson AB, Cooper SC (1995). Fusion of SYT to two genes, SSX1 and SSX2, encoding proteins with homology to the Kruppel-associated box in human synovial sarcoma. *EMBO* 14: 2333–2340.
6. Shipley J, Crew J, Birdsall S, Gill S, Clark J, Fisher C, Kelsey A, Nojima T, Sonobe H, Cooper C, Gusterson B (1996). Interphase fluorescence in situ hybridization and reverse transcription polymerase chain reaction as a diagnostic aid for synovial sarcoma. *Am J Pathol* 148 :559–567.
7. Ackerman LV, Louis ST (1958). Extra-osseous localized non-neoplastic bone and cartilage formation (So-called mytosis ossificans). Clinical and pathological confusion with malignant neoplasms. *J Bone Joint Surg [Am]* 40: 279–298.
8. Bhagavan BS, Dorfman HD (1982). The significance of bone and cartilage formation in malignant fibrous histiocytome of soft tissue. *Cancer* 49: 480–488.
9. Chung EB, Enzinger FM (1987). Extraskeletal osteosarcoma. *Cancer* 60: 1132–1142.
10. Reiman HB, Dahkin DC (1986). Cartilage- and- bone forming tumors of the soft tissue. *Semin Diagn Pathol* 3 :288–305.
11. Winnepeninckx V, De Vos R, Debiec-Rychter M, Samson I, Brys P, Hagemeyer A, Sciot R (2001). Calcificating/ossifying synovial sarcoma shows t(X;18) with SSX2 involvement and mitochondrial calcifications. *Histopathology* 38 :141–145.

12. Oda Y, Hashimoto H, Tsuneyoshi M (1993). Survival in synovial sarcoma. A multivariate study of prognostic factors with special emphasis on the comparison between early death and long term survival. *Am J Surg Pathol* 17:35–44.
13. Soule EH (1986). Synovial sarcoma. *Am J Surg Pathol* 10 :78–82

Corresponding author: Masahito Hatori, Department of Orthopaedic Surgery,
Tohoku University School of Medicine
1-1 Seiryomachi, Aobaku, Sendai, Japan 980-8574
Tel:81-22-717-7242
Fax:81-22-717-7248
mhato@mail.cc.tohoku.ac.jp