

Viscosupplementation with Hyaluronic Acid in Hip Osteoarthritis (a review)

Michele Abate¹, Patrizia Pelotti², Daniele De Amicis³, Angelo Di Iorio⁴, Stefano Galletti², Vincenzo Salini³

¹Postgraduate School of Physical Medicine and Rehabilitation – University “G. D’Annunzio”, Chieti - Pescara – Italy. ²Ultrasonography for Musculoskeletal Pathologies Unit – Istituto Ortopedico Rizzoli – Bologna – Italy. ³Postgraduate School of Orthopaedics and Traumatology – Department of Human Movement Science - University “G. D’Annunzio”, Chieti-Pescara – Italy. ⁴Section of Clinical Epidemiology and Geriatrics – Department of Medicine and Sciences of Aging - University “G. D’Annunzio”, Chieti-Pescara – Italy

Abstract

Background: Viscosupplementation (VS) with hyaluronic acid (HA) is largely used for knee osteoarthritis therapy, but the evidences for its usefulness in hip osteoarthritis (OA) are limited.

Methods: In this review, an extensive search of published trials on VS in hip OA was performed. From the selected papers the following data were extracted: sample size, inclusion / exclusion criteria, treatment procedures, evaluation methods, follow-up duration and clinical outcomes. **Results:** The level of evidence was low in quite all the trials (no placebo controlled groups). A reduction of pain and an improvement of function after 3 months, persistent in the long term (12 – 18 months), was observed. Patients with mild morphological alterations responded better to therapy. Side effects were negligible, and were limited to pain and a sensation of heaviness in the injection site. No clear differences among Low (LMW) and High Molecular Weight (HMW) HA preparations were found in the clinical outcomes. However, for HMW-HA preparations, a lower number of injections was, in general, necessary in order to reach the therapeutic effect.

Conclusions: Despite the initial promising results, some questions still remain open : 1) the characteristics of responders must be more precisely defined; 2) the treatment schedules, at present mainly based on the individual clinical experience, need a proper and accepted standardization. Finally, larger and placebo controlled trials are necessary to confirm the efficacy of VS in hip OA.

Introduction

Osteoarthritis (OA) is a chronic disease, characterized by loss of articular cartilage, subchondral sclerosis, joint deterioration and biochemical and biomechanical alterations of extracellular matrix.

Hip OA is the more common cause of chronic pain and functional impairment, which, in turn, particularly in the elderly, may cause disability (1).

Several therapeutic approaches have been proposed, with the aim of reducing pain and maintaining and / or improving the joint function. None of the therapeutic options available for the treatment of OA , such as analgesics, non steroidal anti-in-

Keywords: Hyaluronic acid, osteoarthritis, joint infiltration

Received 3 April 2008

Accepted 8 May 2008

flammatory drugs (NSAIDs) and COX-2 Inhibitors (2), have been shown to delay the progression of osteoarthritis or reverse joint damage in humans.

Moreover, it is well known that these drugs, mainly in the elderly (3), may cause relevant side effects on gastrointestinal, renal, hepatic and cardiovascular apparatuses (4–6).

The use of corticosteroids in hip OA is controversial, because these drugs are short acting and may cause several adverse effects (7,8). Therefore, drugs with minimal side effects are warranted.

When the conservative approach fails and function is impaired, total hip replacement becomes necessary.

Several studies have confirmed that viscosupplementation (VS) by intra-articular injections of hyaluronic acid (HA) has useful therapeutic effects in the knee in selected patients (9–12) and has been recommended by expert panels as an effective symptomatic slow acting treatment (13).

On the contrary, the number of studies of VS in hip OA is limited. The reason for this can be the deeper localization of the hip joint, being closer to femoral vessels and nerves.

In this review we performed an extensive search of all the papers published on this topic, outlining the more significant results which have been obtained.

Methods of literature analysis

We searched the Medline electronic database from January 1998 to December 2007. Reference lists of relevant articles were controlled for additional references. We used the search terms VS, HA and hip OA. Only original papers, published in medical journals, excluding studies presented in symposia as abstract, were included (14,15). From the papers retrieved in the search the following data were extracted: sample size, inclusion / exclusion criteria, treatment procedures, evaluation methods, clinical results and follow-up duration. The case series, published by Migliore et al. (16–21) and Van den Bekerom et al (22,23), at different times, were considered cumulative. Methodological quality of included studies was assessed by assigning Levels of Evidence as previously defined by the Centre for Evidence Based Medicine (CEBM) (24). In short, for studies on therapy or prognosis, Level I is attributed to well designed and performed randomised controlled trials, Level II are cohort studies, Level III are case-control studies, Level IV are case series and Level V are expert opinion articles.

Hyaluronic acid and its therapeutic use

Hyaluronic Acid, is a polysaccharide, which belongs to the family of polymers termed glycosaminoglycans. It is distributed ubiquitously in different tissues of vertebrates and exerts a lot of biological functions as described in the excellent review recently published by Torvard C. Laurent (25).

Because the aim of this paper is limited to the therapeutic use of HA in hip osteoarthritis, we report briefly some data concerning the biology of HA in joints.

The native HA has a molecular weight of 4–10 millions Daltons (Da) and it is present in articular fluid in a concentration of about 0.35 gr/100 ml. It is produced by synoviocytes, fibroblasts and chondrocytes, and it is an important component of synovial fluid and cartilage.

HA is essential for articular homeostasis (15, 26, 27); it has a protective effect on articular cartilage and soft tissue surfaces of joints, acting as a lubricant and imparting viscoelastic properties to the joint because of its high viscosity (27). In OA the concentration of HA in the joints is reduced: the factors which contribute to the low concentrations of HA are dilutional effects, aberrant hyaluronan synthesis and free radical degradation (22).

When viscoelasticity of synovial fluid is reduced, the transmission of mechanical force to cartilage may increase its susceptibility to mechanical damage. This is the biological basis for the administration of HA into the OA joints, in order to restore the normal articular homeostasis.

The direct injection in the joint space is necessary to reach a proper concentration with low doses, favouring a longer permanence in the joint and therefore the therapeutic response.

HA preparations have a short half-life; therefore the long-term effects of VS cannot solely be attributed to the substitution of HA itself (28). This suggests that clinical efficacy may be mediated by several different pathways: restoration of joint rheology, anti-inflammatory effects, anti-nociceptive effects, normalization of endogenous HA synthesis, and chondroprotection (29).

In experimental rabbit OA, HA inhibits matrix metalloproteinase (MMP) – 3 production (30,31) and decreases the synovial expression of interleukin 1 beta (31). Therefore the chain of events that, from fibronectin fragments, via cytokines, leads to a reduced synthesis of proteoglycans, is blocked (31–34).

At present, preparations with different molecular weight are available. The enhanced penetration of Low Molecular Weight (LMW) preparation (0.5–1.5 millions Da) through the extracellular matrix of the synovium is thought to maximize its concentration and to facilitate its interaction with target synovial cells, so reducing the synovial inflammation (35, 36). Because of the low elastoviscosity of these hyaluronan solutions compared to native hyaluronan in the synovial fluid, interests were shifted to a VS fluid similar to the native HA. Recently, an HA cross-linked (Hylan G-F 20) preparation, with high molecular weight (HMW) (6–7 millions Da), similar to native HA, has been developed.

This formulation, by means of its hydrophilic properties, retain higher amounts of fluid in articular space (36) and is provided by a greater anti-inflammatory activity, as shown by studies on migration of inflammatory cells in the joint and on the reduced PGE2 and bradykinin concentration (32, 37, 38). Moreover, HMW HA is considered more effective in relieving pain, compared to LMW HA.

A novel HA preparation, non-animal stabilised HA (NASHA) has been manufactured by a two stage procedure: biosynthesis of HA by cultured bacteria, fol-

lowed by a mild stabilization process. Stabilisation does not change the biochemical properties of HA but creates a biocompatible gel with improved viscoelastic properties and a longer residence time in the joint, compared with a non stabilised HA preparation (39).

Currently, with the aim of favouring a longer presence of HA in the joint, long acting preparations are under study (40, 41). Hopefully, these preparations with better rheological and biological properties could influence positively the natural history of OA disease. The presence of fluid inside the joint reduces the therapeutic efficacy, probably due to a dilution effect.

Techniques of infiltration

Problems of hip joint infiltration are related to its deep localization and the proximity of sensitive structures such as femoral vessels and nerves.

When hip joint infiltration is performed blindly, the failure rate is very high, as shown by studies in human cadavers using anatomic landmarks. Leopold et al. (42) have reported that neither the anterior nor the lateral approach for hip injection results in a clinically acceptable rate of correct intra-articular needle placement. Moreover, in blind condition, lesions of femoral nerves and vessels may occur, due to their frequent anatomic variability.

Therefore, “image-guided” infiltration techniques with fluoroscopy or ultrasound are currently used. These techniques share important advantages : first, they allow a correct insertion of the needle in the capsular recess, and make sure that HA is injected properly inside and not outside the hip joint (43); second, they offer the possibility of performing a synovial lavage; finally, the procedure may be performed in the ambulatory setting, without need of hospital stay.

After 1–2 hour of rest following the injection, the patients can return to their homes with the advice to rest throughout the day. The use of analgesic, in case of intolerable pain, is allowed.

Ultrasound-guided injection

A 5–10 MHz multi-frequency linear or a 3.5 MHz convex probe, aligned with the long axis of the femoral neck, are used. The patient’s position varies according to the approach selected by the operator. In sterile conditions, intra-articular injection is performed by inserting a 22–20 gauge spinal needle (90–120 mm).

When the injection is performed antero-inferiorly, it is possible to inject the HA preparation at basis of the femoral neck and a complete evacuation of intra-articular fluid, if present, is allowed (Fig. 1) (16, 44).

The antero-superior parasagittal approach allows the injection over the femoral head, so that the drug is evenly distributed on the cartilage both of femoral head and acetabulum (Fig. 2).

Also a lateral approach is possible, injecting the preparation near the great trochanter’s tuberosity (45). Most of Authors perform the procedure “free hand” (43, 45, 46), but others (18), using the biopsy guide, claim that the positioning of the

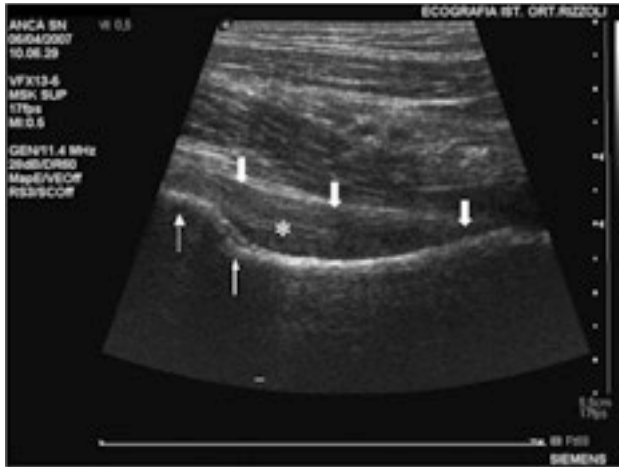


Figure 1. Ultrasound imaging of hip joint : a 13.5 MHz multifrequency linear probe was used. Small arrows : anterior margin of the articular space - Asterisk : Articular recess - Arrow : femoral head - Broken arrow: femoral neck.

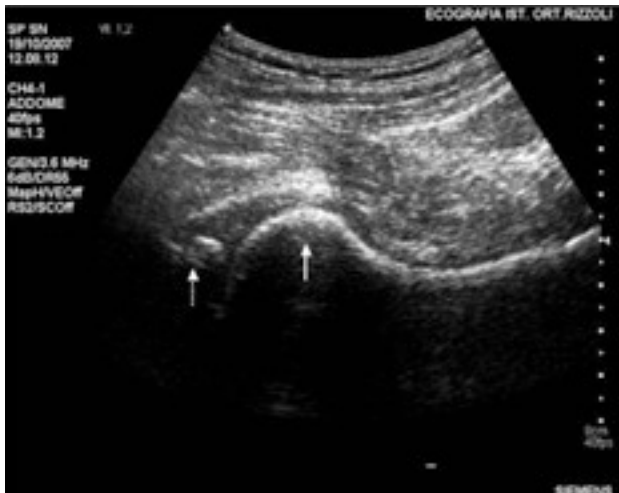

Figure 2. Ultrasound imaging of hip joint: a 3.5 MHz convex probe was used. Broken arrow: acetabulum - Solid arrow: femoral head.

needle is simpler, quicker and more accurate (16). Moreover, utilising a real-time biopsy guidance software, the progression of the needle into the capsular recess may be monitored, so optimizing the procedure.

The proper position of the needle is usually confirmed by the introduction of a local anaesthetic or saline and afterwards by the direct visualization of viscous HA fluid, which is injected (Fig. 3) (47). The accuracy of ultrasound guided procedure has been confirmed by simultaneous computed tomography (43).

Fluoroscopy-guided injection

Using fluoroscopic guidance, the proper position of the needle is assessed by injecting a small amount of iodinate contrast medium. HA is injected, using a procedure similar to that described for echography (48).

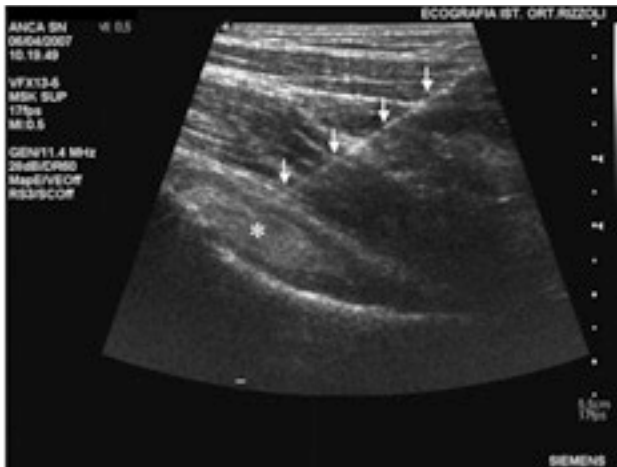


Figure 3: Ultrasound guided injection : a 13.5 MHz multifrequency linear probe was used. Arrows: position of the needle – Asterisk: Hyaluronic Acid in the articular space.

Ultrasound vs. fluoroscopy

The ultrasound-guided injection is simple, fast (7–10 minutes), economic and safe; it does not require the use of contrast media (47), allowing the infiltration in patients intolerant to iodized contrasts. It can be repeated without limits, allows an easy visualization of fluid in the articular recess and shows how narrow the articular space is. Moreover, it is able to reveal the position of the needle, and, by means of continuous color doppler monitoring (47), to evaluate its distance from the femoral vessels (47). Finally, ultrasound technique allows the visualization of the viscous fluid inside the joint (47).

The more important limitation is represented by the reduced visual field, due to the deep localization of the hip joint, particularly in obese patients.

On the contrary, the visual field obtained by means of fluoroscopy is larger, ranging from the acetabulum to the femoral neck. Moreover, fluoroscopy allows a very proper positioning of the needle in joints where the articular space is very narrow.

However, besides these advantages, many problems must be considered. Fluoroscopy does not show the presence of fluid, is associated with radiation and contrast media use (47), which may be intolerated by some patients and can dilute the HA preparation inside the articular recess, does not allow identification and avoidance of vascular and nervous structures (43,47) and must be performed in the radiological setting. Therefore it is more time consuming and more expensive.

Clinical studies

In the literature we found 17 clinical studies on the therapy of hip OA with HA. It is very difficult to compare these studies because they differ in several characteristics, such as inclusion criteria, outcomes evaluated, procedure of treatment, schedule of administration of HA and preparations of HA injected. The comparison is made more difficult by the different follow-up periods and modalities of expression of results.

Table 1. Inclusion criteria in clinical trials

		Level of evidence	Degree of severity	Pain
Author	Year	CEBM score	Kellegren – Lawrence Score	VAS Score
Brocq	2001	IV-	1–3	≥ 40
Vad*	2003	IV-	1–4	
Conrozier*	2003	IV	2–3	50 - 90
Migliore	2003-06	IV	1–4	
Caglar – Yagci	2004	IV+	1–3	
Berg	2004	IV-	2–3	
Tikiz	2005	I	1–3	≥ 50
Pourbagher	2005	IV-	**	
Qvistgaard	2006	I	1–4	
Van Den Bekerom	2006	IV	4	> 30
Gaston*	2007		0–4	

* In these studies an evaluation of joint space width was performed.

** Hartofilakidis scale (score : 1–2).

Levels of evidence (Tab. 1)

The level of evidence, according to the Center for Evidence Based Medicine (CEMB) criteria (24), is low in the majority of studies, a score I having been assigned only to Tikiz's (49) and Qvistgaard's studies (46). To other studies a score IV has been assigned, because they are cohort studies and lack a reference group (16–23, 29, 39, 43–45, 50).

Inclusion criteria

Patients included in all the studies had similar demographic characteristics (range of age, sex, BMI). The diagnosis of primary hip osteoarthritis was made by means of radiologic examination, according to the American College of Rheumatology (ACR) criteria (2).

In the majority of cases the Kellgren-Lawrence (K-L) score (51) was intermediate; only few patients with low score (K-L I) were included (45, 49–51) and only Vad, Migliore, Van Den Bekerom, Qvistgaard, Gaston (17, 18, 20, 22, 23, 29, 46, 48) included patients which were candidates for hip replacement (K-L IV).

Visual analog scale (VAS) pain score, evaluated as mean of previous 3 months, ranged from 50 to 90 mm.

Exclusion criteria

Exclusion criteria, in general, were evidence of rapidly destructive hip OA, mus-

culo-skeletal diseases (rheumatoid arthritis, chondrocalcinosis, psoriasis, gout), oral anticoagulant therapy, oral or intra-articular administration of corticosteroids within the last 3 months, severe chronic disorders (cardiovascular, renal, metabolic, etc), and hypersensitivity to HA. Obviously, patients with absence of any articular space were also excluded.

Treatment methodologies (Tab. 2)

In the studies, both low (16, 19, 23, 43, 46, 49) and high (14, 17, 18, 20–23, 29, 39, 45, 48–50) molecular weight preparations were used. The numbers of injections ranged from 1 to 3 for each patients and only in few cases 4 or 5 injections were performed. In general the number of injections was lower for HMW preparations. The interval between injections ranged from 1 (29, 43, 45, 48, 49) to 2, 4 or more weeks (16–20, 22, 23). These criteria were largely arbitrary, mainly based on the clinical experience and on the relief obtained by the patients.

Outcome measures (Tab. 3)

The following outcome measures were taken into account:

1. Pain evaluation (VAS score) (52);
2. Articular function (Western Ontario and McMaster Universities-WOMAC – Lequesne Index) (53, 54);
3. NSAIDs consumption (16–21).

Table 2. Sample size and treatment schedules

Author	Number of patients	Number of injections / patients	Interval (weeks)
Brocq	22	1.36	4
Vad	22	3.4	1
Conrozier	57	1.56	4
Migliore	146	2.14	2–12
Caglar – Yagci	14	3	1
Berg	31	1	–
Tikiz	43	3.9	1
Pourbagher	10	3	1
Qvistgaard	101	3	2
Van Den Bekerom	180	1.03	2
Gaston	13	3.46	1

The number of injections has been evaluated as a mean: so, in Berg's and in Van Den Bekerom's studies, only one injection / patient was performed, whereas in Vad's, Tikiz's and Gaston's studies, some patients received 1 or 2 injections and others more than 4 injections. In some studies, the number of injections is over-rated, because patients with bilateral hip OA received treatment in both joints affected.

Table 3. Outcome parameters evaluated by means of: Visual Analogic Scale (Pain) (52); Western Ontario and McMaster Universities-WOMAC and Lequesne Index (Articular function) (53,54).

Author	Pain		Articular function		NSAID-Consumption	
	VAS (↓%)		WOMAC (↓%) Score		Lequesne (↓%) Index (↓%)	
	< 3 mths	3-6 mths	< 3 mths	3-6 mths	< 3 mths	3-6 mths
Brocq	39.13	50.59			37.51	51.29
Vad ^a	73.56					
Conrozier ^b	< 50 %	48.2	< 50 %	59.3		
	> 50 %	51.8	> 50 %	40.7		
Migliore ^c	35.77	31.07		26.81	29.47	36.61
Caglar-Yagci	52.26				36.63	66.6
Berg ^d				43.2		
Tikiz	35.83	39.0	35.64	41.5	45.07	48.0
Pourbagher	42.77	45.77	47.11	50.83		58.0
Qvistgaard	16.1			13.68	8.86	
Van Den Bekerom ^e	38.58					
Gaston ^e				79.79		

^a In this study the American Academy of Orthopaedic Surgeons (AAOS) Lower Limb Core Scale was used : the improvement in articular function was 94.79 % (F-U 12 months)

^b The percentages of patients who had improvement are reported (F-U 3 months).

^c Mean values obtained in 6 studies. Three studies report the following values :

i. 12 months : VAS - 33,29 %; WOMAC - 39,73%; Lequesne - 30,11%; NSAIDs - 41,85 %

ii. 18 months : VAS - 36,4 %; WOMAC - 41,72 %; NSAIDs - 52 %.

^d In this study at 6 - 11 months after treatment, the result remained satisfactory (WOMAC - 40,5 % compared to baseline). These results are referred to patients (16/31) included in the extended study (mean F-U 6-11 months).

^e In these studies the Harris Hip Scale (HHS) was used :

i. in Gaston's study no significant improvement in function and activities of daily living was reported.

ii. in Van Den Bekerom's study a mild improvement was registered (+11 %).

Only in a few studies objective functional measures were obtained, such as “walking speed”, “time to sit on and stand up from a chair 10 times” or “time to go up and down 20 stairs” (45, 49, 50).

Results

Due to several limits previously mentioned, data reported in the tables have been extracted from papers as means and therefore they are simply indicative. All the trials have shown a reduction of pain, which, in general, becomes evident within 3 months and persists in the following months (table 3).

Only few studies report a precocious reduction of the pain: within a week, according to Brocq (-27%) (50), and within the first 2–4 weeks according to Qvistgaard (-14% and -32%, respectively) (46).

The positive effects on pain after 1–3 months range from -16.1 % to -52.2% (mean -37.2%), whereas, overall, the mean VAS score decreases about 49% after 3–6 months (range 31–80%).

Therefore, it seems that the benefit increases in the long term. However, it must

Table 4. Hyaluronic acid preparations, imaging guidance methods and incidence of side effects

Author	HA	Guidance	Cumulative number of injections	Side effects %
Brocq	HMW	Fluoroscopy	30	10
Vad	HMW	Fluoroscopy	75	0
Conrozier	HMW	Fluoroscopy	176	3.4
Migliore	LMW - HMW	Ultrasound	175	6.8
Caglar – Yagci	HMW	Ultrasound	42	7.14
Berg	NASHA	Fluoroscopy	31	29.03
Tikiz	LMW - HMW	Fluoroscopy	168	3.57
Pourbagher	LMW	Ultrasound	30	0
Qvistgaard	LMW	Ultrasound	99	3.03
Van Den Bekerom	LMW - HMW	Fluoroscopy	186	16.23
Gaston	HMW	Fluoroscopy	45	0
Fluoroscopy			711	8.89
Echography			346	4.24
Total			1047	6.56

HMW: High molecular weight

LMW: Low molecular weight

NASHA: Non animal stabilised HA (HMW)

be underlined that only few studies report longer follow-up periods : at 12 months (18) and at 18 months (21) (VAS -36.4%) , with persistent benefit on the pain. Besides the reduction of pain, also the articular function is improved. The WOMAC score is reduced about 32% (range 14–47 %) after 3 months, and about 40% (range 27%–51%) at 6 months).

Studies with longer follow-up periods show a persistent benefit in the long term (-40% at 12 months and -42% at 18 months) (18, 21).

Also in studies, in which the Lequesne Index was used, the improvement was of a similar degree (-32% [range 9–45%] in the first month; -45% [range 37–61%] at 3–6 months; -30% at 12 months). Positive effects of the HA treatment are observed using other evaluation scales (+ 11% with Harris Hip Score [HHS] and + 95% with American Academy of Orthopaedic Surgeons [AAOS] Lower Limb Core Scale) (23,29,48). A further observation, which confirms the previous data, was the reduction of NSAIDs consumption of more than 60% after 3 months and about 50% after 12–18 months.

The treatment had beneficial effects also on the objective measures of performance: the walking speed increased 16% after 3 months and 22% after 6 months. In the “Time to sit on and stand up from a chair” test, and in the “Time to go up and down stairs” test, the improvements were respectively 16% and 26% at 6 months (45).

Responders and no-responders

The benefit was not equally distributed among patients, some of them being non-responders to the therapy. Although at present all the characteristics of responders have not been clearly identified, some authors claim that a greater benefit may be obtained in patients with low grade hip OA (44, 46, 48, 50, 55). On the contrary, age does not influence the therapeutic response (46).

Low versus high molecular weight HA preparations

Although in vitro studies have generally shown that HMW-HA preparations are more biologically active than LMW-HA compounds, these findings have not been confirmed in animal studies and clinical trials. The percentages of improvement in all the outcome measures was similar in the trials in which LMW-HA and HMW-HA were used separately and also in the trials specifically designed in order to assess differences about the preparations. However the number of injections needed was in general lower for HMW HA preparations and this is not a negligible advantage for the patients (49).

HA versus corticosteroid and placebo

Only in one study the clinical efficacy of HA-VS was compared to that of corticosteroids and placebo. This very large trial, including 101 patients, has not shown significant differences between the treatments, after 3 months (46). However, within

this time period, an improvement was found, clearly evident in the steroid group and moderate in HA group, compared to placebo.

The authors claim that this effect may be attributed to the efficacy of corticosteroids and HA in relieving acute pain in the short term, without any positive activity of either drug in the long term (46).

Side effects

Several factors may contribute to the onset of side effects : among them, the characteristics and amount of the HA preparation injected, the number of injections, the skill of the operator, the technique of imaging used and the local and systemic tissues reactions. In the clinical trials no general side effects were observed. Some patients reported a sensation of heaviness and pain in their hip after injection (39). These effects were more frequent in studies performed under fluoroscopic guidance in comparison with ultrasound guidance (mean 8.89 [range 0–29.03%] vs 3.61% [range 0–7.14%]). No differences were observed in relation to HA preparation used (data not reported).

Side effects usually disappeared after 2–7 days without any therapeutic intervention and did not limit basic or instrumental activities of daily living.

Vascular or nervous complications were not reported, neither gout nor chondrocalcinosis, sometimes observed after OA VS of the knee.

Septic arthritis (only two cases with Hylan G-F 20, each preceded by steroid IA injections) or aseptic synovial effusion occurred rarely (50, 56) and the number of injections did not affect the cumulative risk of side effects (55).

Discussion

On the basis of the published trials it appears that VS therapy with HA is a safe and effective method in the treatment of hip OA resistant to conventional treatment modalities.

The use of HA is mainly recommended when NSAIDs are contraindicated or badly tolerated, when NSAIDs or corticosteroids are inefficient or in young patients candidates to hip replacement. VS significantly reduces pain within 3 months and this beneficial effect is maintained in the long term (12–18 months). The articular function is improved and therefore patients can rapidly come back to work and to social activities.

Only few trials have shown a very early improvement, which has been related to the lubricating effect of hyaluronate in “dry” joints, as reported in studies of VS in knee OA, and/or to a short term placebo effect (50).

The reduction in NSAID consumption is another important clinical achievement with significant health economic considerations (6). Not only direct costs (purchasing of NSAIDs), but also the indirect costs associated with management of side effects of NSAIDs, are saved.

Cost-benefit analysis is difficult in comparison with corticosteroids. Corticosteroids are cheaper than HA, but the effect of these drugs seems to have a shorter life time than the HA preparations, with more relevant side effects, which can offset the initial saving (46).

Patients with mild morphological alterations, and with preserved articular space, are more responsive to treatment (22, 48, 50); the results are less encouraging in patients with severe OA (K-L IV), only few studies report good therapeutic effects (20, 22, 48). In this regard, Bekerom has observed that VS may delay or avoid hip replacement in 45% of patients, so reducing costs and mortality (22).

Articular effusion is usually associated with a reduced therapeutic effect due to the “dilution effect” of the drug (46). In this situation, Qvistgaard has shown a better therapeutic response with intrarticular corticosteroid, probably linked to its anti-inflammatory activity (46).

The better biological activity, shown by HMW-HA preparations *in vitro*, has not been confirmed in clinical trials (49). In fact, the percentage of improvement is similar, in study performed by Caglar-Yagci, with LMW-HA and HMW-HA preparations (45). An advantage of HMW HA may be the reduced number of the injections needed in order to obtain the therapeutic effect.

The VS is safe, without any systemic or local side effects, excluding the pain of the injections and a sensation of heaviness for a few hours/days after treatment. The very high tolerability of the preparation allows the contemporary use of other drugs, which may be helpful, in polypharmaceutically treated patients.

In spite of these very promising results, several questions are still open.

1. It must be remembered that, for ethical reasons, almost all the studies lack a reference group treated with placebo: so the level of evidence of the trials, according to CEBM criteria, is low. Only one study was performed on a large cohort, comparing HA, corticosteroids and placebo. In this trial corticosteroids and HA reduced the pain after one month, but this effect was no more evident after 3 months (46).
2. The sample size in several studies was too small for drawing definitive conclusion about treatment efficacy. Thus, future studies with a large number of patients are necessary to confirm results.
3. Inclusion and exclusion criteria were largely different and therefore the characteristics of patients who are more responsive to treatment are not clearly defined. The identification of these patients is therefore, strongly recommended.
4. No consensus exist about the doses of HA, the interval between doses and the number of injections, which are more effective in the different clinical situations. Qvistgaard et al. suggest that an interval of at least 2 weeks between injections must be observed (46), because this interval is long enough to exclude the occurrence of a septic arthritis or soft tissues inflammation. A 3 doses regimen is usually recommended, but studies which compare different treatment schedules are lacking (49).
5. It is also debated whether HMW HA has to be preferred to LMW HA. Some authors prefer to use HMW HA because these preparations have a longer half-life.

The different modalities of treatment are largely arbitrary, mainly based on the clinical experience and on the therapeutic response of patients.

6. Interpretation of results is made difficult by the different degree of severity of OA, genetic and biological characteristics of patients enrolled in the studies and by concurrent therapies with other drugs and rehabilitation treatments (16, 29, 44, 49, 50).

Conclusion

Despite the absence of placebo controlled trials and the small number of patients included in the studies, the IA injection of HA seems to have a symptomatic effect in patients with painful hip OA.

In order to confirm these promising data and to recognize better responders, large scale double-blind controlled studies with a longer follow-up period are needed.

Indeed, it must be remembered that there is a strong placebo effect from joint injections, which may cause a nearly 30% reduction in pain relief during the first 2 weeks (49, 50, 57–59).

Furthermore, the differences of safety and efficacy between HA preparations and the best dose regime must be established before definitely recommending VS for the treatment of patients suffering from hip OA.

References

1. Lawrence, R. C., Helmick, C. G., Arnett, F. C., Deyo, R. A., Felson, D. T., Giannini, E. H., Heyse, S. P., Hirsch, R., Hochberg, M. C., Hunder, G. G., Liang, M. H., Pillemer, S. R., Steen, V. D., and Wolfe, F. (1998). Estimates of the prevalence of arthritis and selected musculoskeletal disorders in the United States. *Arthritis Rheum.* 41: 778–799
2. Altman, R., Alarcon, G., Appelrouth, D., Bloch, D., Borenstein, D., Brandt, K., Brown, C., Cooke, T. D., Daniel, W., Feldman, D., and . (1991). The American College of Rheumatology criteria for the classification and reporting of osteoarthritis of the hip. *Arthritis Rheum.* 34: 505–514
3. Page, J. and Henry, D. (2000). Consumption of NSAIDs and the development of congestive heart failure in elderly patients: an underrecognized public health problem. *Arch.Intern.Med.* 160: 777–784
4. Hochberg, M. C., Altman, R. D., Brandt, K. D., Clark, B. M., Dieppe, P. A., Griffin, M. R., Moskowitz, R. W., and Schnitzer, T. J. (1995). Guidelines for the medical management of osteoarthritis. Part I. Osteoarthritis of the hip. *American College of Rheumatology. Arthritis Rheum.* 38: 1535–1540
5. Psaty, B. M. and Furberg, C. D. (2005). COX-2 inhibitors--lessons in drug safety. *N.Engl.J.Med.* 352: 1133–1135
6. Sturkenboom, M. C., Romano, F., Simon, G., Correa-Leite, M. L., Villa, M., Nicolosi, A., Borgnolo, G., Bianchi-Porro, G., and Mannino, S. (2002). The iatrogenic costs of NSAID therapy: a population study. *Arthritis Rheum.* 47: 132–140
7. Flanagan, J., Casale, F. F., Thomas, T. L., and Desai, K. B. (1988). Intra-articular injection for pain relief in patients awaiting hip replacement. *Ann.R.Coll.Surg.Engl.* 70: 156–157
8. Plant, M. J., Borg, A. A., Dziedzic, K., Saklatvala, J., and Dawes, P. T. (1997). Radiographic patterns and response to corticosteroid hip injection. *Ann.Rheum.Dis.* 56: 476–480

9. Altman, R. D. (2000). Intra-articular sodium hyaluronate in osteoarthritis of the knee. *Semin. Arthritis Rheum.* 30: 11–18
10. Kolarz, G., Kotz, R., and Hochmayer, I. (2003). Long-term benefits and repeated treatment cycles of intra-articular sodium hyaluronate (Hyalgan) in patients with osteoarthritis of the knee. *Semin. Arthritis Rheum.* 32: 310–319
11. Raynauld, J. P., Torrance, G. W., Band, P. A., Goldsmith, C. H., Tugwell, P., Walker, V., Schultz, M., and Bellamy, N. (2002). A prospective, randomized, pragmatic, health outcomes trial evaluating the incorporation of hylan G-F 20 into the treatment paradigm for patients with knee osteoarthritis (Part 1 of 2): clinical results. *Osteoarthritis.Cartilage.* 10: 506–517
12. Tamir, E., Robinson, D., Koren, R., Agar, G., and Halperin, N. (2001). Intra-articular hyaluronan injections for the treatment of osteoarthritis of the knee: a randomized, double blind, placebo controlled study. *Clin.Exp.Rheumatol.* 19: 265–270
13. Pendleton, A., Arden, N., Dougados, M., Doherty, M., Bannwarth, B., Bijlsma, J. W., Cluzeau, F., Cooper, C., Dieppe, P. A., Gunther, K. P., Hauselmann, H. J., Herrero-Beaumont, G., Kaklamanis, P. M., Leeb, B., Lequesne, M., Lohmander, S., Mazieres, B., Mola, E. M., Pavelka, K., Serni, U., Swoboda, B., Verbruggen, A. A., Weseloh, G., and Zimmermann-Gorska, I. (2000). EULAR recommendations for the management of knee osteoarthritis: report of a task force of the Standing Committee for International Clinical Studies Including Therapeutic Trials (ESCISIT). *Ann. Rheum.Dis.* 59: 936–944
14. Chevalier, X., Conrozier T, Bertin, P, Bailleul, F, and Vignon, E (2000). Treatment of patients with symptomatic hip OA. A pilot study with intra-articular Hylan G-F 20 (synvisc). *Arthritis Rheum.* 43 (suppl.): 384
15. Lanzotti, SB, Machado, MB, Nascimento, RA, Souza, SAA, Araujo-Junior, JC, and Torres, VNM (2000). Intra articular sodium hyaluronate in unilateral coxofemoral osteoarthritis treatment. *Arthritis Rheum.* 43 (suppl): 336
16. Migliore, A., Martin, L. S., Alimonti, A., Valente, C., and Tormenta, S. (2003). Efficacy and safety of viscosupplementation by ultrasound-guided intra-articular injection in osteoarthritis of the hip. *Osteoarthritis.Cartilage.* 11: 305–306
17. Migliore, A., Tormenta, S., Martin, L. S., Valente, C., Massafra, U., Granata, M., and Alimonti, A. (2005). Open pilot study of ultrasound-guided intra-articular injection of hylan G-F 20 (Synvisc) in the treatment of symptomatic hip osteoarthritis. *Clin.Rheumatol.* 24: 285–289
18. Migliore, A., Tormenta, S., Valente, C., Massafra, U., Martin, L. S., Carmenini, E., Bernardini, A., and Alimonti, A. (2005). [Intra-articular treatment with Hylan G-F 20 under ultrasound guidance in hip osteoarthritis. Clinical results after 12 months follow-up]. *Reumatismo.* 57: 36–43
19. Migliore, A., Tormenta, S., Massafra, U., Carloni, E., Padalino, C., Iannesi, F., Alimonti, A., Martin, L. S., and Granata, M. (2005). Repeated ultrasound-guided intra-articular injections of 40 mg of Hyalgan may be useful in symptomatic relief of hip osteoarthritis. *Osteoarthritis.Cartilage.* 13: 1126–1127
20. Migliore, A., Tormenta, S., Martin, L. S., Iannesi, F., Massafra, U., Carloni, E., Monno, D., Alimonti, A., and Granata, M. (2006). The symptomatic effects of intra-articular administration of hylan G-F 20 on osteoarthritis of the hip: clinical data of 6 months follow-up. *Clin.Rheumatol.* 25: 389–393
21. Migliore, A., Tormenta, S., Massafra, U., Martin, L. S., Carloni, E., Padalino, C., Alimonti, A., and Granata, M. (2006). 18-month observational study on efficacy of intraarticular hyaluronic acid (Hylan G-F 20) injections under ultrasound guidance in hip osteoarthritis. *Reumatismo.* 58: 39–49
22. Van Den Bekerom, M. P., Mylle, G., Rys, B., and Mulier, M. (2006). Viscosupplementation in symptomatic severe hip osteoarthritis: a review of the literature and report on 60 patients. *Acta Orthop.Belg.* 72: 560–568
23. Van Den Bekerom, M. P., Rys, B., and Mulier, M. (2008). Viscosupplementation in the hip: evaluation of hyaluronic acid formulations. *Arch.Orthop.Trauma Surg.* 128 (3): 275–280
24. Fletcher, B and Sackett, DL (1979). Canadian task force on the periodic health examination: the Periodic Health Examination. *CMAJ* 121: 1193–1254
25. Laurent T.C. (2007). Hyaluronan Research in Uppsala. *Upsala J Med Sci* 112: 123–142
26. O'Regan, M., Martini, I., Crescenzi, F., De Luca, C., and Lansing, M. (1994). Molecular mechanisms and genetics of hyaluronan biosynthesis. *Int.J.Biol.Macromol.* 16: 283–286

27. Van Den Bekerom, M. P., Lamme, B., Sermon, A., and Mulier, M. (2007). What is the evidence for viscosupplementation in the treatment of patients with hip osteoarthritis? Systematic review of the literature. *Arch.Orthop.Trauma Surg.* [Epub ahead of print; DOI 10.1007/s00402-007-0447-z]
28. Kikuchi, T., Yamada, H., and Fujikawa, K. (2001). Effects of high molecular weight hyaluronan on the distribution and movement of proteoglycan around chondrocytes cultured in alginate beads. *Osteoarthritis.Cartilage.* 9: 351–356
29. Vad, V. B., Sakalkale, D., Sculco, T. P., and Wickiewicz, T. L. (2003). Role of hylan G-F 20 in treatment of osteoarthritis of the hip joint. *Arch.Phys.Med.Rehabil.* 84: 1224–1226
30. Han, F., Ishiguro, N., Ito, T., Sakai, T., and Iwata, H. (1999). Effects of sodium hyaluronate on experimental osteoarthritis in rabbit knee joints. *Nagoya J.Med.Sci.* 62: 115–126
31. Takahashi, K., Goomer, R. S., Harwood, F., Kubo, T., Hirasawa, Y., and Amiel, D. (1999). The effects of hyaluronan on matrix metalloproteinase-3 (MMP-3), interleukin-1beta(IL-1beta), and tissue inhibitor of metalloproteinase-1 (TIMP-1) gene expression during the development of osteoarthritis. *Osteoarthritis.Cartilage.* 7: 182–190
32. Goto, H., Onodera, T., Hirano, H., and Shimamura, T. (1999). Hyaluronic acid suppresses the reduction of alpha2(VI) collagen gene expression caused by interleukin-1beta in cultured rabbit articular chondrocytes. *Tohoku J.Exp.Med.* 187: 1–13
33. Homandberg, G. A., Hui, F., Wen, C., Kuettner, K. E., and Williams, J. M. (1997). Hyaluronic acid suppresses fibronectin fragment mediated cartilage chondrolysis: I. In vitro. *Osteoarthritis. Cartilage.* 5: 309–319
34. Williams, J. M., Plaza, V., Hui, F., Wen, C., Kuettner, K. E., and Homandberg, G. A. (1997). Hyaluronic acid suppresses fibronectin fragment mediated cartilage chondrolysis: II. In vivo. *Osteoarthritis.Cartilage.* 5: 235–240
35. Bagga, H., Burkhardt, D., Sambrook, P., and March, L. (2006). Longterm effects of intraarticular hyaluronan on synovial fluid in osteoarthritis of the knee. *J.Rheumatol.* 33: 946–950
36. Ghosh, P. and Guidolin, D. (2002). Potential mechanism of action of intra-articular hyaluronan therapy in osteoarthritis: are the effects molecular weight dependent? *Semin.Arthritis Rheum.* 32: 10–37
37. Aihara, S., Murakami, N., Ishii, R., Kariya, K., Azuma, Y., Hamada, K., Umamoto, J., and Maeda, S. (1992). Effects of sodium hyaluronate on the nociceptive response of rats with experimentally induced arthritis. *Nippon Yakurigaku Zasshi* 100: 359–365
38. Forrester, J. V. and Balazs, E. A. (1980). Inhibition of phagocytosis by high molecular weight hyaluronate. *Immunology* 40: 435–446
39. Berg, P. and Olsson, U. (2004). Intra-articular injection of non-animal stabilised hyaluronic acid (NASHA) for osteoarthritis of the hip: a pilot study. *Clin.Exp.Rheumatol.* 22: 300–306
40. Larsen, N. E., Leshchiner, E. A., Parent, E. G., Hendrikson-Aho, J., Balazs, E. A., and Hilal, S. K. (1991). Hylan gel composition for percutaneous embolization. *J.Biomed.Mater.Res.* 25: 699–710
41. Weiss, C. and Band, P. (1995). Musculoskeletal applications of hyaluronan and hylan. Potential uses in the foot and ankle. *Clin.Podiatr.Med.Surg.* 12: 497–517
42. Leopold, S. S., Battista, V., and Oliverio, J. A. (2001). Safety and efficacy of intraarticular hip injection using anatomic landmarks. *Clin.Orthop.Relat Res.* 192–197
43. Pourbagher, M. A., Ozalay, M., and Pourbagher, A. (2005). Accuracy and outcome of sonographically guided intra-articular sodium hyaluronate injections in patients with osteoarthritis of the hip. *J.Ultrasound Med.* 24: 1391–1395
44. Conrozier, T., Bertin, P., Mathieu, P., Charlot, J., Bailleul, F., Treves, R., Vignon, E., and Chevalier, X. (2003). Intra-articular injections of hylan G-F 20 in patients with symptomatic hip osteoarthritis: an open-label, multicentre, pilot study. *Clin.Exp.Rheumatol.* 21: 605–610
45. Caglar-Yagci, H., Unsal, S., Yagci, I., Dulgeroglu, D., and Ozel, S. (2005). Safety and efficacy of ultrasound-guided intra-articular hylan G-F 20 injection in osteoarthritis of the hip: a pilot study. *Rheumatol.Int.* 25: 341–344
46. Qvistgaard, E., Christensen, R., Torp-Pedersen, S., and Bliddal, H. (2006). Intra-articular treatment of hip osteoarthritis: a randomized trial of hyaluronic acid, corticosteroid, and isotonic saline. *Osteoarthritis.Cartilage.* 14: 163–170
47. Migliore, A., Tormenta, S., Martin Martin, L. S., Valente, C., Massafra, U., Latini, A., and Ali-

- monti, A. (2004). [Safety profile of 185 ultrasound-guided intra-articular injections for treatment of rheumatic diseases of the hip]. *Reumatismo*. 56: 104–109
48. Gaston, M. S., Tiemessen, C. H., and Philips, J. E. (2007). Intra-articular hip viscosupplementation with synthetic hyaluronic acid for osteoarthritis: efficacy, safety and relation to pre-injection radiographs. *Arch.Orthop.Trauma Surg.* 127: 899–903
49. Tikiz, C., Unlu, Z., Sener, A., Efe, M., and Tuzun, C. (2005). Comparison of the efficacy of lower and higher molecular weight viscosupplementation in the treatment of hip osteoarthritis. *Clin. Rheumatol.* 24: 244–250
50. Brocq, O., Tran, G., Breuil, V., Grisot, C., Flory, P., and Euler-Ziegler, L. (2002). Hip osteoarthritis: short-term efficacy and safety of viscosupplementation by hylan G-F 20. An open-label study in 22 patients. *Joint Bone Spine* 69: 388–391
51. Kellgren, J. H. and Lawrence, J. S. (1957). Radiological assessment of osteo-arthritis. *Ann. Rheum.Dis.* 16: 494–502
52. de Nies, F. and Fidler, M. W. (1997). Visual analog scale for the assessment of total hip arthroplasty. *J.Arthroplasty* 12: 416–419
53. Bellamy, N., Buchanan, W. W., Goldsmith, C. H., Campbell, J., and Stitt, L. W. (1988). Validation study of WOMAC: a health status instrument for measuring clinically important patient relevant outcomes to antirheumatic drug therapy in patients with osteoarthritis of the hip or knee. *J.Rheumatol.* 15: 1833–1840
54. Lequesne, M. G. (1997). The algofunctional indices for hip and knee osteoarthritis. *J.Rheumatol.* 24: 779–781
55. Conrozier, T., Bertin, P., Bailleul, F., Mathieu, P., Charlot, J., Vignon, E., Treves, R., and Chevalier, X. (2006). Clinical response to intra-articular injections of hylan G-F 20 in symptomatic hip osteoarthritis: the OMERACT-OARSI criteria applied to the results of a pilot study. *Joint Bone Spine* 73: 705–709
56. Chazerain, P., Rolland, D., Cordonnier, C., and Ziza, J. M. (1999). Septic hip arthritis after multiple injections into the joint of hyaluronate and glucocorticoid. *Rev.Rhum.Engl.Ed* 66: 436
57. Egsmose, C., Lund, B., and Bach, Andersen R. (1984). Hip joint distension in osteoarthritis. A triple-blind controlled study comparing the effect of intra-articular indoprofen with placebo. *Scand.J.Rheumatol.* 13: 238–242
58. Kirwan, J. (2001). Is there a place for intra-articular hyaluronate in osteoarthritis of the knee? *Knee.* 8: 93–101
59. Ravaud, P., Moulinier, L., Giraudeau, B., Ayral, X., Guerin, C., Noel, E., Thomas, P., Fautrel, B., Mazieres, B., and Dougados, M. (1999). Effects of joint lavage and steroid injection in patients with osteoarthritis of the knee: results of a multicenter, randomized, controlled trial. *Arthritis Rheum.* 42: 475–482

Corresponding author:

Michele Abate
Postgraduate School of Physical Medicine and Rehabilitation
University “G. D’Annunzio”
Via dei vestini 5, Chieti scalo
Italy
Phone +39-0871-551150; Fax +39-0871-551150
e-mail: mic.abate@libero.it

