

## **Pulmonary Nocardiosis with Brain Abscess in a Sensitized Kidney Transplant Recipient with History of Repeated Graft Loss and HLA-Antibody Depletion Treatment – A case report**

Ali-Reza Biglarnia<sup>1</sup>, Jonas Wadström<sup>1</sup>, Gunnar Tufveson<sup>1</sup>, Britt-Marie Eriksson<sup>2</sup>

<sup>1</sup>*Department of Surgical Sciences, Section of Transplantation Surgery and* <sup>2</sup>*Department of Infectious Diseases, Uppsala University Hospital, Uppsala, Sweden*

### **Abstract**

Nocardiosis is an opportunistic infection with unfavourable prognosis and is predominantly seen in immunocompromised patients. We here present a kidney transplant recipient with a history of two early graft losses who subsequently developed Human Leukocyte Antigen (HLA)-antibodies and underwent a desensitization treatment with plasmapheresis and monoclonal anti-CD20 antibody application. However, 3 months after a third HLA-identical kidney transplantation he developed Nocardiosis with pulmonary and asymptomatic brain manifestation. The present case report exemplifies this opportunistic infection and gives an overview of the literature.

### **Case report**

A 59-year-old man underwent his first kidney transplantation 1988 due to chronic glomerulonephritis. He suffered from an early severe acute rejection and graft rupture, which resulted in removal of the graft within a week after the transplantation. In 1989 he received a second kidney transplant with excellent primary graft function and normal serum creatinine on 5<sup>th</sup> postoperative day (POD). The immunosuppressive therapy given was cyclosporin A, cyclophosphamide and steroids. However, the postoperative course was rapidly complicated with start on 6<sup>th</sup> POD, when a severe rejection was diagnosed. Despite an aggressive treatment with OKT3 (anti-CD3 monoclonal antibody), high dose steroids and plasmapheresis, the kidney function rapidly deteriorated and the graft was removed 3 months after the second transplantation. Subsequently, the patient became broadly sensitized with panel reactive antibody (PRA) >50%. In 1998 he was re-evaluated for a third kidney transplantation but during the following years on the waiting list, no immune compatible kidney graft could be allocated. In order to reduce the Human Leukocyte Antigen (HLA)-antibody level, he underwent an HLA-antibody depletion treatment in 2003 with a single dose of rituximab (anti-CD20 monoclonal antibody) combined with plasmapheresis. This treatment resulted in a temporary decrease of the PRA and complete depletion of CD20 positive B-cells for at least 6 months.

In May 2005 he was successfully re-transplanted with an HLA-identical kidney graft with excellent primary function. The immunosuppression combined induction

---

Received 27 August 2007

Accepted 16 October 2007

treatment with basiliximab (monoclonal IL-2R $\alpha$  antibody), tacrolimus, MMF and steroids. Clinical or histological signs of rejection were not observed. Pentamidine-inhalations were given for pneumocystis jiroveci pneumonia prophylaxis and the patient was discharged 3 weeks postoperatively with a normalized serum creatinine value. One month later a cytomegalovirus (CMV)-infection was diagnosed and successfully treated with ganciclovir.

Three months after the third transplantation the patient was hospitalized for sub-febrile temperature and frequent cough. No symptoms from the gastrointestinal or urinary tract were presented. Clinical and neurological examinations were unremarkable. Graft function was stable with serum creatinine in normal range. However, chest radiography revealed multiple pulmonary nodules in the right middle lobe and both apical lobes (Fig. 1). In order to verify an etiological basis, samples from blood and sputum were collected and a CT-guided biopsy from one of the pulmonary nodules was performed. Subsequently, an ex juvantibus treatment with meropenem and liposomal amphotericin B was started. Histological examination of the lung biopsy showed extended inflammatory infiltration without any signs of malignant cells, fungi, acid-fast rods and other bacteria. Polymerase chain reaction (PCR) of blood for CMV, Epstein-Barr virus (EBV), Human polyoma virus, Candida, Aspergillus and of broncho-alveolar lavage for mycobacterium tuberculosis/bovis and pneumocystis jiroveci were all negative.

Cultures and microscopy of sputum revealed initially nothing but normal flora. However, after 2 weeks of culturing, growth of gram-positive branching bacteria of type *Nocardia farcinica* was demonstrated in sputum samples as well as in lung tissue. Consequently, a cranial MRI-scan was performed that revealed a solitary abscess formation in the right temporal lobe (Fig. 2). The patient had no neurological disorder at any time. As a consequence of the diagnosis, amphotericin B was replaced by trimethoprim/sulfamethoxazole (TMX/SMX). The effectiveness of meropenem and TMX/SMX was confirmed by in vitro susceptibility testing. In order to verify the immune status of the patient with a history of OKT3 and rituximab applications, a lymphocyte subset analysis was performed, which revealed a slight decrease in number of CD4 (+) T-helper cells (data not shown). The number of CD19 (+) and CD20 (+) B-cells, however, was in the normal range.

The patient was discharged 4 weeks after the initiation of antibiotic treatment with excellent general condition and normal graft function. At 6-months follow-up the chest radiography was unremarkable and the cranial CT-scan revealed a significant regression of the CNS-manifestation as a result of good response to TMX/SMX therapy, which was continued for 12 months.

## Discussion

This case report exemplifies the history of a serious *Nocardia* infection in an immunocompromised kidney transplant recipient who had faced two therapy-resistant episodes of acute rejections resulting in loss of two grafts. Subsequently the patient

became broadly sensitized and underwent an HLA-antibody depletion treatment. However, 16 years after the second transplantation he received an HLA-identical kidney graft with good primary function and no rejection complications but faced a life threatening *Nocardia* infection with pulmonary and brain manifestations.

Since 1969 this is the first patient in our transplant unit presenting with this unusual infectious disease which is caused by an ubiquitous aerobic gram positive environmental branching bacteria belonging to the genus of actinomycetes species (1). Of note, *Nocardia asteroides* complex is the most important strain and accounts for 90% of Nocardiosis in transplant recipient patients. It consists of *N. farcinica*, *N. asteroides sensu strictu* and *N. nova* (2). Nocardiosis is usually acquired by inhalation of spores resulting in pulmonary involvement in 90% of cases (3). Cutaneous penetration is another route of transmission with formation of cutaneous nodules (4). Because of the high tendency of hematogenous dissemination brain, kidney, joints, bones and eyes are non-pulmonary sites of manifestation (5).

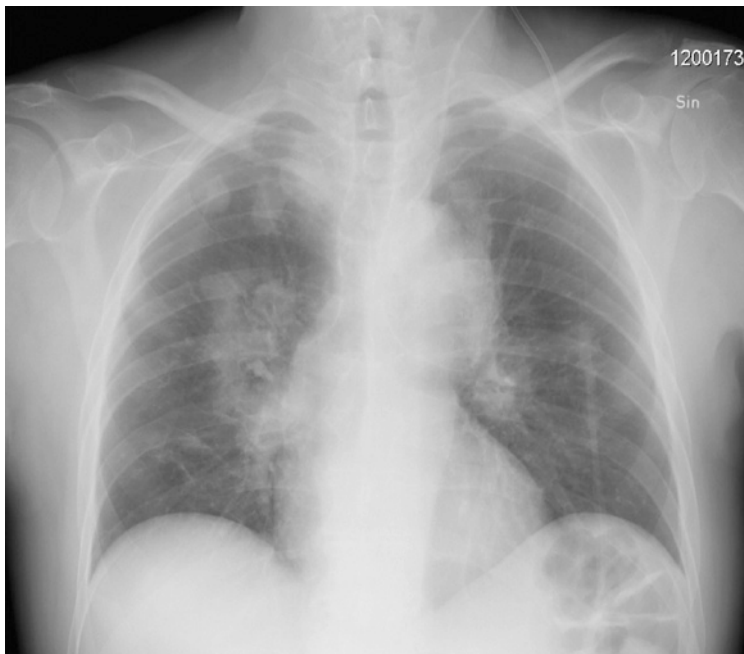
The incidence of *Nocardia* infection for geographically defined populations amounts to 0.3-0.4 per 100 000 per year. However, immunocompromised individuals such as transplant recipients suffer from an elevated incidence of Nocardiosis up to 340 times compared to geographically defined populations, which points out the immunosuppression as the main risk factor (6). Further risk factors are HIV-, CMV-infection, long-term corticosteroid treatment and lymphoreticular malignancy. The infection is also more common among men (2-3:1) and among individuals of the age <10 and >40 (7, 8).

The diagnosis of *Nocardia* is difficult and time-consuming and comprises isolation of *Nocardia* species from blood, urine, airway-samples and biopsies and it can take from a couple of days to weeks to confirm the suspicion (1). TMP/SMX is the drug of choice in the acute and chronic treatment of Nocardiosis achieving high tissue concentrations in lung, brain, skin and bone (9). As initial therapy carbapenems can be added with TMP/SMX for patients with pulmonary and cerebral manifestations. Final choice of antibiotic treatment is, however, dependent on the susceptibility testing, since some strains of *Nocardia* such as *N. nova*, *N. otitidiscaviarum* and especially *N. farcinica* may have high-grade resistance to sulfamethoxazole (10). In cases of sulfamethoxazole resistance linezolid is the agent of choice, since it is effective against all species of *Nocardia* including *N. farcinica* (11). Prolonged linezolid treatment can, however, be limited by serious myelosuppression, including neutropenia, thrombocytopenia and anemia (12).

In the literature the duration of treatment of Nocardiosis is not well defined and recommendations are empirical. However, all transplant recipients should be treated for at least 12 months. Facing the tendency of nocardial infections to relapse, even a life long treatment is recommended (9). Patients with brain abscess have to be followed up very closely, since the mortality rate is reported to be up to 90%. In cases of missing responsiveness to antibiotics, surgical removal of brain abscesses is indicated (13).

In summary, *Nocardia* infection is an unusual but not rare infection that predominantly occurs in immunosuppressed patients. Facing the unfavourable prognosis,

Nocardiosis should always be considered in the presence of sudden pulmonary and non-pulmonary nodules in transplant recipients. Since the diagnosis of *Nocardia* is a challenging procedure the microbiologist must be informed about the suspicion. In order to optimize diagnosis and enable detection of infections with a similar clinical pattern such as aspergillosis and tuberculosis, air-way samples should be completed with a percutaneous lung biopsy, if possible. CNS-manifestation of *Nocardia* is associated with a high mortality and often initially asymptomatic. In this context cranial CT- or MRI-scan and close follow-ups are mandatory, since in case of aggravation of neurological symptoms or enlargement of intracerebral lesions surgical intervention is indicated. Finally, regularly pentamidine-inhalations can not prevent *Nocardia* infection in transplant recipient patients. Thus TMP/SMX may be superior to prevent both *Pneumocystis jiroveci* pneumonia and *Nocardia* infection. However, in kidney transplant recipients the nephrotoxic side effect of TMP/SMX must be considered especially if a poor graft function is present.



*Figure 1.* Chest x-ray with multiple nodules in right middle lobe and bilateral apical lobes.

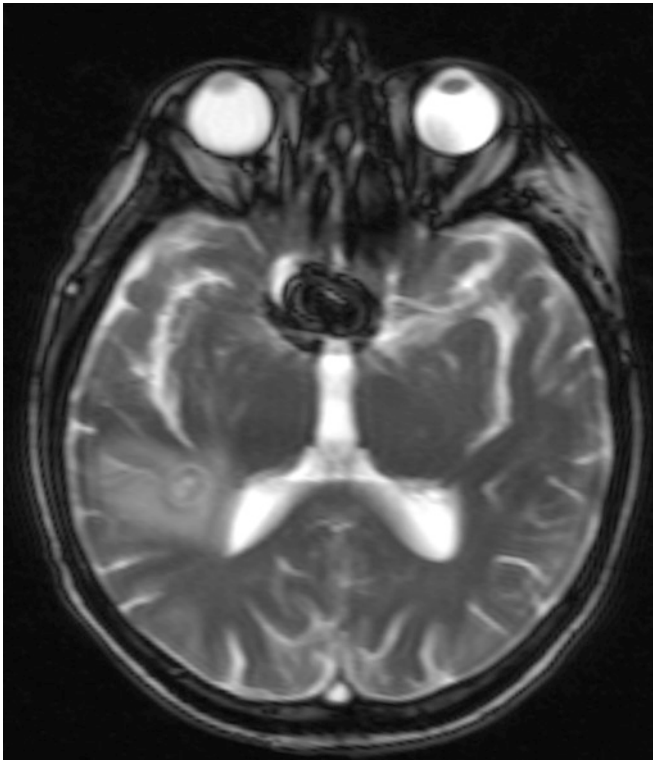


Figure 2. Single brain abscess in the right temporal lobe with capsula enhancement

## References

1. McNeil MM, Brown JM (1999). The medically important aerobic actinomycetes: epidemiology and microbiology. *Clin Microbiol Rev.* 7: 357–417.
2. Arduino RC, Johnson PC, Miranda AG (1993). Nocardiosis in renal transplant recipients undergoing immunosuppression with cyclosporine. *Clin Infect Dis.* 16: 505–12.
3. Maccario M, Tortorano AM, Ponticelli C (1998). Subcutaneous nodules and pneumonia in a kidney transplant recipient. *Nephrol Dial Transplant.* 13: 796–8.
4. Merigou D, Beylot-Barry M, Ly S, Doutre MS, Texier-Maugein J, Billes P, et al (1998). Primary cutaneous *Nocardia asteroides* infection after heart transplantation. *Dermatology.* 196: 246–7.
5. Torres OH, Domingo P, Pericas R, Boiron P, Montiel JA, Vazquez G (2000). Infection caused by *Nocardia farcinica*: case report and review. *Eur J Clin Microbiol Infect Dis.* 19: 205–12.
6. Filice GA (2005). Nocardiosis in persons with human immunodeficiency virus infection, transplant recipients, and large, geographically defined populations. *J Lab Clin Med.* 145: 156–62.
7. Fishman JA, Rubin RH (1998). Infection in organ-transplant recipients. *N Engl J Med.* 338: 1741–51.
8. Lerner PI (1996). Nocardiosis. *Clin Infect Dis.* 22: 891–903.
9. Smego RA, Jr., Moeller MB, Gallis HA (1983). Trimethoprim-sulfamethoxazole therapy for *Nocardia* infections. *Arch Intern Med.* 143: 711–8.
10. Khan Z, Al-Sayer H, Chugh TD, Chandy R, Provost F, Boiron P (2000). Antimicrobial susceptibility profile of soil isolates of *Nocardia asteroides* from Kuwait. *Clin Microbiol Infect.* 6: 94–8.
11. Brown-Elliott BA, Ward SC, Crist CJ, Mann LB, Wilson RW, Wallace RJ, Jr (2001). In vitro

- activities of linezolid against multiple *Nocardia* species. *Antimicrob Agents Chemother.* 45: 1295–7.
12. Kuter DJ, Tillotson GS (2001). Hematologic effects of antimicrobials: focus on the oxazolidinone linezolid. *Pharmacotherapy.* 21: 1010–3.
  13. Hall WA, Martinez AJ, Dummer JS, Lunsford LD (1987). Nocardial brain abscess: diagnostic and therapeutic use of stereotactic aspiration. *Surg Neurol.* 28: 114–8.

Corresponding author:

Ali-Reza Biglarnia

Department of Surgical Sciences, Section of Transplantation

Uppsala University Hospital

SE-75185 Uppsala, Sweden

Telephone: +46-18-6110000

Fax: +46-18-553601

E-mail: [alireza.biglarnia@akademiska.se](mailto:alireza.biglarnia@akademiska.se)