

## **Calcified Leiomyosarcoma Simulating Uterine Myoma in a Patient with Long-standing Anaemia**

Sven Nilsson,<sup>1</sup> Håkan Ahlström<sup>1</sup> and Folke Nilsson<sup>2</sup>

*Departments of <sup>1</sup>Diagnostic Radiology and <sup>2</sup>Surgery, Akademiska sjukhuset,  
University of Uppsala, Uppsala, Sweden*

### **ABSTRACT**

A case of small bowel leiomyosarcoma in a 75-year-old woman is reviewed. The patient had an unexplained anaemia with occult blood in the faeces for at least 15 years. The value of different radiological investigations in patients with suspected gastrointestinal bleeding is discussed. The possible significance of calcifications visible on plain abdominal films is emphasized.

### **INTRODUCTION**

The small intestine is the site of less than 2 % of all primary gastrointestinal malignancies (1,2,5). The rarity of these lesions means that they will only occasionally be seen by individual radiologists and surgeons. Calcifications, however, are frequently observed on plain abdominal radiographs (6), but they seldom lead the radiologist to suspect a small bowel tumour.

In this report we present a case which clearly illustrates this fact and also gives reason to discuss further the value of different radiological techniques in patients with suspected gastrointestinal bleeding, and the interpretation of the findings.

## CASE REPORT

A 75-year-old woman had had anaemia of the sideropenic type, with occult blood in the faeces, for at least 15 years. Gastroscopy and radiological gastrointestinal investigations, including small bowel follow-through and double-contrast examination of the colon, had been

performed several times without any pathological results. Total colonoscopy was carried out in March 1985 and a few vascular irregularities that were thought to be angiodysplastic lesions were observed in the caecal area. For this reason the patient was referred for surgery, which was undertaken at her home county hospital in April 1985. A right-sided hemicolectomy and ileo-transverso-stomy was performed. At operation, extensive adhesions binding parts of the small bowel firmly behind the uterus were seen. This area was not further explored. Macroscopically the resected specimen appeared to exhibit very slight vascular changes, although histologically the picture was quite normal. The patient continued to bleed and a month postoperatively her haemoglobin concentration was 67 g/l. Further investigations, including scintigraphy - to rule out a bleeding Meckel's diverticulum - and ultrasound of the abdomen, did not yield any positive results.

The patient was referred to our hospital and angiography of the superior and inferior mesenteric arteries was performed. In the close vicinity of a 2.5 x 1.5 cm pelvic calcification, irregular capillaries were observed and in the parenchymal phase there was contrast enhancement of a 2.5 x 5.0 cm area (Fig. 1). There were also signs of arteriovenous shunting. No changes were apparent in the area of the inferior mesenteric artery. A few days later the duodenum was intubated and a double-contrast examination of the small-bowel was performed. Close to the calcification a rounded small-bowel tumour, 2.5 cm in diameter was demonstrated. In the vicinity of the tumour there was also contrast filling of a presacral cavity, about 5 cm in diameter (Fig. 2).

At operation the adhesions behind the uterus were carefully dissected and a hard tumour, 4-5 cm in diameter and firmly adherent to the sacrum and uterus, was found. The findings in frozen sections indicated a malignant tumour of a sarcomatous nature. This diagnosis was supported by the macroscopic appearance, with spread of tumour islands at the pelvic rim. The tumour could be bluntly and sharply dissected but microscopic radicality was not thought to have been achieved. A resection of 10 cm of the small bowel was performed. There was

extensive bleeding during the operation, due to venous drainage from the area. Continuous postoperative bleeding necessitated re-operation after four hours. A tamponade had to be used to control the bleeding.

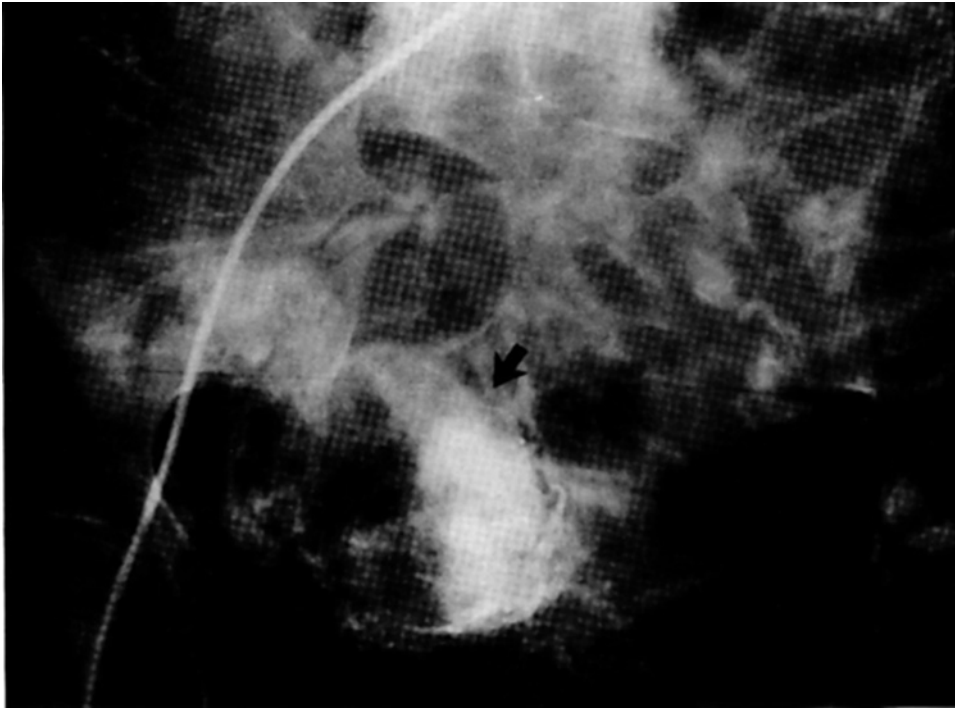

Fig. 1. Angiography of the superior mesenteric artery, parenchymal phase. Irregular dilated veins are draining the tumour (arrows).

Histological examination showed a cystic tumour 5 cm in size with central calcification. The final diagnosis was small bowel leiomyosarcoma.

The postoperative course was complicated by liver and renal failure and terminal signs of sepsis. Plain abdominal films taken from this period showed that the calcification had been removed. At autopsy no evidence of local infection was found and there were no signs of tumour either macro- or microscopically in the operation area or in the small bowel on either side of the anastomosis. The uterus proved to be normal.

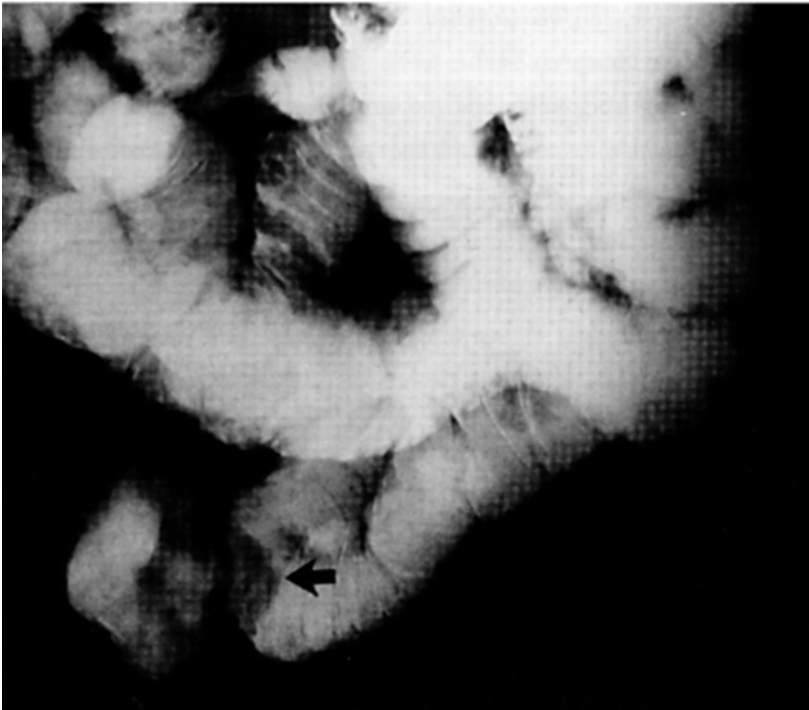


Fig. 2. Double contrast small bowel examination. The cystic tumour is easily demonstrated (arrow).

## DISCUSSION

Calcifications may appear in most parts of the human body as signs of a pathological process. They are fundamental in the radiologist's daily work and, if correctly interpreted, frequently offer a simple key to the diagnosis (6). The pathogenesis of dystrophic calcification, i.e. deposition of calcium due to local changes without any general disturbance of calcium metabolism, is still poorly understood (7). Such calcifications occur in inflammatory processes and in tissues undergoing uncontrolled growth, as in benign or malignant tumours. In both cases there is a shift in the chemical environment so that insoluble calcium salts are more likely to precipitate. Among gastro-intestinal malignancies carcinoids, adenocarcinoma of the colon and leiomyosarcoma are those which most frequently display calcifications (6,8).

In the present case gastrointestinal bleeding was obviously taking place, but gastroscopy and repeated barium examinations of the gastrointestinal canal had been non-diagnostic. Because of

persistent back pain the patient has also been referred for lumbar spine radiographs, which were performed four times in the years 1984 and 1985. The finding was general osteoporosis with progressive multiple compression fractures. A pelvic calcification can be seen retrospectively in several of these lumbar radiographs (Fig. 3). It resembles a calcified uterine myoma and was probably interpreted as such by the radiologists concerned. In view of the patient's unexplained anaemia, it might have aroused suspicion of a calcified intestinal tumour.

The angiographic appearance of carcinoid tumours in the small intestine is often characteristic, with a stellate arterial configuration (4). Leiomyosarcomas may yield a similar picture, as in our case.

It is worthy of note that several conventional follow-through examinations had failed to reveal the patient's tumour. Even retrospectively nothing pathological but a post right hemicolectomy status can be found in these films, of which only those from 1985 are available. With knowledge of the angiographic appearance, however, the tumour could easily be demonstrated with a double contrast technique following duodenal intubation. The high percentage of non-diagnostic barium examinations of the small intestine has been noted by several authors (3,5).

#### CONCLUSIONS

Calcifications visible on overview films of the abdomen or pelvis should always be carefully regarded as possible keys to the diagnosis. The present case illustrates the diagnostic difficulties in patients with gastrointestinal haemorrhage, when gastroscopy and barium examinations of the oesophagus, stomach, small intestine and colon have failed to disclose the source of the bleeding. In this situation angiography should be tried. In cases of a small bowel tumour a double-contrast barium examination is more likely to reveal the diagnosis than a conventional follow-through.

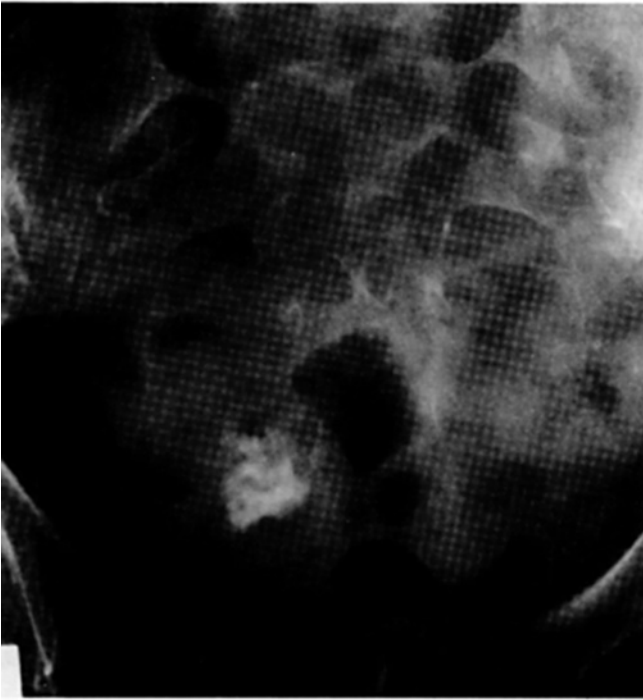

Fig.3 a

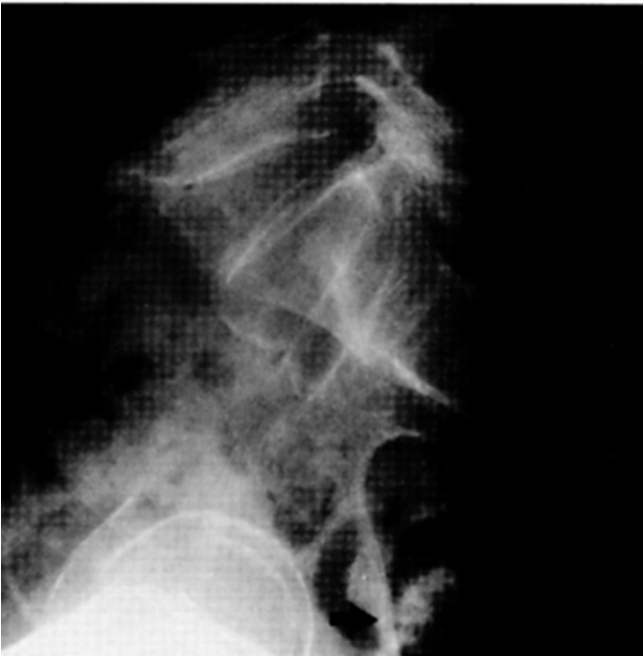

Fig. 3 b

Figs 3 a and b. Frontal (a) and lateral (b) plain radiographs of the lumbo-sacral region. The calcification is visible in front of the lower end of the sacrum (arrows).

## REFERENCES

- 1.Cancer incidence in Sweden 1981. the Cancer Registry, National Board of Health and Welfare (eds), p. 92. Allmänna förlaget, Stockholm, 1984.
- 2.Cooper, M.J. & Williamson, R.C.N.: Enteric adenoma and adenocarcinoma. *World J Surg* 9:914-920, 1985.
- 3.Ekberg, O. & Ekholm, S.: Radiography in primary tumours of the small bowel. *Acta Radiol Diagnosis* 21:79-84, 1980.
- 4.Jeffree, M.A., Barter, S.J., Hemingway, A. P. & Nolan D.J.: Primary carcinoid tumours of the ileum: The radiological appearances. *Clin Radiol* 35:451-544, 1984.
- 5.Johnson, A.M., Harman, P.K. & Banks, J.B.: Primary small bowel malignancies. *Am Surg* 51:31-36, 1985.
- 6.McAffee, J. & Donner, M.W.: Differential diagnosis of calcification encountered in abdominal radiographs. *Am J Med Sci* 243:609-649, 1962.
- 7.Robbins, S.L., Angell, M. & Kumar, U.: *Basic Pathology*. 3rd ed., pp 25-26. Philadelphia, 1981.
- 8.Wolf, B.S. & Khilnani M.T.: Plain film diagnosis of gastrointestinal lesions. In : *Alimentary tract roentgenology* ( ed. R. Margulis & H.J. Burhenne ). 3rd ed., p. 170., Mosby, St. Louis, 1973.

Address reprint requests to:

Doctor Sven Nilsson  
Department of Diagnostic Radiology  
Akademiska sjukhuset  
S-751 85 Uppsala, Sweden