

# **Inferior Colliculus and Related Descending Pathways in Rat**

*Minireview based on a doctoral thesis*

Hilde Faye-Lund

*Ear-Nose-Throat Department, Ullevål Hospital, Oslo, Norway*

## INTRODUCTORY REMARKS ON EFFERENT PATHWAYS.

Both ascending and descending sensory pathways have relays which form feed-back circuits of varied sizes and complexities. These circuits regulate the sensitivity of the sensory organ and the central propagation of the impulses. This prevents damage of the sensory organ, and the passage of too many impulses. The damping of the input also implies the possibility of selection of impulses and discrimination within a broad range of intensity of the specific stimulus. Through connections with other parts of the central nervous system the relays make possible interaction on several levels, both between different sensory systems and between such and centers for visceral and somatomotor controle.

Grant Rasmussen's (37) discovery of the olivocochlear bundle represented a breakthrough concerning the research of the efferent projection to sensory organs. The descending auditory pathways, however, are still less known than the ascending ones. The present thesis consists of three parts which deal with the inferior colliculus (IC) and the descending pathways connected to this structure.

In the present review the results will first be referred to (including a discription of paper I-III), then the anatomical parcellation of the IC will be studied in the light of the

experimental findings. In the final discussion the findings will be evaluated in a functional connection, with special emphasis on the olivocochlear system and the middle ear reflexes. The findings are based on light microscopy and consequently can not give any information about synaptic contacts. The functional considerations are consequently uncertain.

#### SUMMARY OF THE RESULTS.

Earlier investigations on auditory descending projections have mostly been done in cat (33, 38, 39, 2, 6, 24, 32). The present project was based on rat as the experimental animal. The main reason for this was that the large olivocochlear neurons which represent the last link in the descending tract to the outer haircells in cochlea, are located more concentrated in rat than in other species. Consequently in rat the cells are easy to study as a group (45, 35).

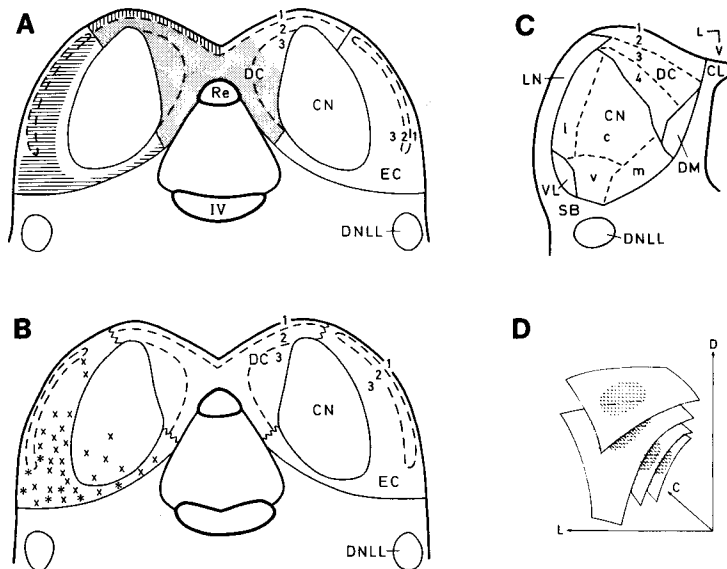
Due to economical reasons, the rat is increasingly popular in research. It is therefore a growing demand for neuroanatomical knowledge of this animal.

The three separate papers in this thesis are all concentrated on IC. This part of the midbrain has a key position in the auditory system as a near obligatory relay both for ascending and descending pathways. In line with this IC is found to have the highest spontaneous activity in the rat brain (15). Except for a preliminary report (4) there was no anatomical description of IC in rat. To interpret the findings concerning the connections from the auditory cortex to IC and from IC to the superior olivary complex, it was necessary to study its normal anatomy.

In the following a brief summary of each of the three papers included in the thesis is given.

## I. ANATOMY OF THE INFERIOR COLLICULUS IN RAT (20).

This project was based on Golgi, Nissl and cell-myelin stained sections in the transversal, sagittal and horizontal planes. As shown in Fig. 1A,B, IC was divided into three subdivisions, a central nucleus, an external cortex and a dorsal cortex.



**Fig. 1.** Schematic drawings of IC. A-B are from rat (paper I-III) and indicate partition of IC in a central nucleus (CN), a dorsal cortex (DC) and an external cortex (EC). The two cortices each consists of three layers (1-3). **A** shows the terminal area of the descending fibers from different neocortical areas (shaded part from area 41, vertical lines from area 36 and horizontal lines from area 22). **B** shows the localization of neurons projecting to the superior olivary complex (small cells, crosses; large cells, asterisks). **C** shows Morest and Oliver's (1984) map of IC in cat. CN is divided in a central (c), lateral (l), ventral (v) and medial (m) part and DC in layer 1-4. The rest consists of the lateral (LN), ventrolateral (VL) and dorsomedial (DM) nucleus. **D** shows Stiebler and Ehret's (1985) reconstruction of isofrequency planes in IC in mouse. The criss-cross area indicates the part with low threshold for tone respons. Other abbreviations: C, caudal; CL, lateral nucleus of the commissure; D, dorsal; DNLL, dorsal nucleus of the lateral lemniscus; L, lateral; Re, collicular recess; SB, subcollicular area; V, ventral; IV, the 4. ventriculus.

The central nucleus was defined according to the occurrence of cells with flat dendritic trees giving the nucleus a laminated

appearance in Golgi sections. This is in agreement with the findings of Morest (31). The lamellae are an important structural basis for the tonotopic organization of the central nucleus. In rat the central nucleus is relatively smaller than in cat. It is dish-shaped and located more caudal and medial in IC. Ventrally, laterally and rostrally it is surrounded by the external cortex, dorsally and caudally by the dorsal cortex. In Nissl sections the cells seem smaller and more densely packed than in the adjacent subdivisions. Especially dorsally a certain pallisade-like arrangement may be seen. Both cell size and packing density show an axis perpendicular to the dendritic lamellae, with the smallest overall cell size and the biggest cell density dorsally.

The two cortical subdivisions both consist of three layers. Most superficially is layer 1, which is common for the two cortices. This layer makes a fibrocellular capsule which surrounds most of IC.

In the external cortex layer 2 is composed of numerous small and medium sized cells partly aggregated in dense clusters in a myelin rich neuropil. This layer has previously been ignored. In a preliminary report (47) it is claimed that the somatosensory input to the external cortex is localized to cell aggregates which could correspond to layer 2. In the rat atlas of Paxinos and Watson (36), layer 2 is extremely conspicuous because of a distinct acetylcholinesterase positivity. Layer 3 constitutes the main part of the external cortex. In addition to small and medium sized cells, this layer contains large multipolar cells which are especially numerous ventrolaterally. Because of the above mentioned gradient in cell size and density in the central nucleus, the border between layer 3 of the

external cortex and the central nucleus is particularly blurred in the ventral part of IC, both in Nissl and Golgi sections.

The dorsal cortex appears less clearly laminated in all sections. Layer 2 is mostly composed of small cells, while layer 3 in addition contains medium sized cells, especially at the border against the central nucleus.

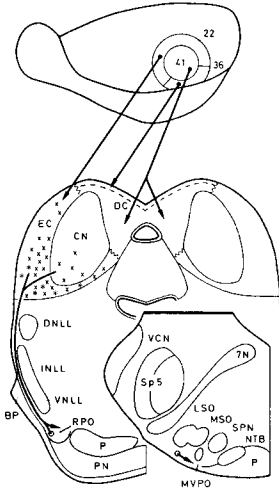
The relation of the different levels of IC to neighbouring structures, mainly the parts of the ventricular system, turned out to be of great help in the following experimental material.

## **II. THE NEOCORTICAL PROJECTION TO THE INFERIOR COLLICULUS IN THE ALBINO RAT (18).**

In this paper the projection from the auditory cortex to IC was studied by using fiber degeneration after large cortical lesions and anterograde transport of conjugated HRP (WGA-HRP) after small cortical applications. The results speak in favor of three separate projections from three origins in the neocortex and with separate destinations in IC. As seen in Fig.1A,2, the neocortical fibers project to the dorsal and external cortex in IC. The central nucleus however does not receive any direct neocortical input.

One of the main problems in this paper was to identify auditory neocortical areas. This was due to lack of landmarks on the smooth surface of the rat brain, and the lack of a cortical map. In addition to Krieg's map(27) of rat neocortex, Caviness's (13) map of mouse neocortex was used. As a test the labelling of cells and terminals in the medial geniculate body were used. The projections of the separate parts of this structure are known from studies by the same researchers (14). Thus area 41 was found to project to layer 2 and 3 of the dorsal cortex bilaterally, area 22 to layer 2 and the superficial part of layer 3 of the

external cortex ipsilaterally and area 36 to layer 1 of the dorsal cortex ipsilaterally.



**Fig. 2.** This semidiagrammatic drawing shows part of the descending auditory pathways in rat. It includes the auditory cortex, inferior colliculus, pons and the superior olivary complex and summarizes the results of the studies. The crosses (small cells) and asterisks (large cells) indicate the actual mean number of colliculoolivary cells in a 50um thick section. The auditory cortical areas 41,22 and 36 have different targets in the colliculus. Only area 22 supplies the superficial part of layer 3 of the external cortex (EC), which gives rise to fibers descending further to subcollicular levels. The field of origin of the colliculoolivary fibers in addition includes the deepestmost part of EC and the adjacent part of the central nucleus (CN). The colliculoolivary fibers terminate in the rostral (RPO) and medioventral (MVPO) zones of the ipsilateral periolivary region (terminal field indicated by shading). The direct bilateral projection from IC to the cochlear nuclei is not indicated.

### III. PROJECTION FROM THE INFERIOR COLLICULUS TO THE SUPERIOR OLIVARY COMPLEX IN THE ALBINO RAT (19).

In this paper the colliculoolivary projection was found by degeneration studies and by antero- and retrogradely transported free and conjugated HRP applied in IC and the superior olivary complex. Olivocochlear cells were identified by acetylcholinesterase positivity (34,44). Cells projecting from the superior olivary complex to the cochlear nuclei were localized by retrogradely transported WGA-HRP. Control applications of WGA-HRP into the cochlear nuclei and pons spoke against any contamination of the olivocochlear system from these structures.

As shown in Fig.1B,2, the colliculoolivary fibers were shown to originate from layer 3 in the external cortex and the adjacent part of the central nucleus. The fibers terminated in the rostral and medioventral zone of the ipsilateral periolivary region(Fig.2). The terminal area constitutes a continuous band overlapping carefully the large olivocochlear cells (35, 45) and smaller periolivary cells projecting to the cochlear nuclei (3). These cell types mainly have a crossed projection. Judged from the findings in the light microscope, both celltypes could constitute the next link in a descending projection to the outer hair cells (22,23) and/or cells in the cochlear nuclei on the opposite side. It is doubtful, however, if IC fibers make contact with periolivary cells which ascend to IC. These kind of cells were found outside the termination area of the descending fibers. This was also the case with the superior periolivary nucleus. This nucleus is typical for rodents and may represent a special development of periolivary cells projecting to the ipsilateral IC.

In addition, according to investigations in cat (33,3) a direct projection from IC to the cochlear nuclei, was found. This projection is bilateral and originates from a larger part of IC since the cells of origin occupy layer 3 of the external cortex in addition to the central nucleus. This projection probably is quantitative larger than the colliculoolivary projection.

#### **DIVISION OF THE INFERIOR COLLICULUS IN ACCORDANCE TO THE EXPERIMENTAL FINDINGS.**

The simple division of IC in three parts used in this project, accords more or less with Cajal's (12) classic partition in human and other vertebrates and with Willard and Ryugo's (48) observations in mouse. The partition is simpler than the one

launched by Geniec and Morest (21) in Golgi studies in human being and in cat (32). The advantages of the more simple partition are that it is easily applicable to individual sections of experimental material even in series in which the direction of sectioning is not optimal. The usefulness is also supported by the fact that the afferent and efferent systems in large respect the cytologically defined borders.

As suggested in Fig. 1A, the dorsal and external cortices differ from the central nucleus by receiving fibers from neocortex. The two cortical areas differ in receiving input from different areas of neocortex. The dorsal cortex differs from the other two divisions by the lack of neurons with a descending projection (Fig.1B). The cytologically defined layers have specific afferent and efferent connections. In the dorsal cortex layer 1 and layer 2-3 receive input from area 36 and 41 respectively. In the external cortex both layer 2 and 3 receive fibers from area 22, while only layer 3 participate in the descending projection to the superior olivary complex.

The cytologically ill-defined border between layer 3 of the external cortex and the ventral part of the central nucleus remains problematic in several ways: The terminal area of the neocortical fibers in the external cortex includes in addition to layer 2 only the superficial part of layer 3 and therefore does not have a "natural" central limitation (Fig.1A). The direct bilateral projection to the cochlear nuclei (not illustrated) originates in layer 3 of the external cortex and the entire central nucleus, and does not respect the border between the two subdivisions. Therefore it is natural to ask: "Is Morest's division of IC more suitable?"

By comparing the scheme of Morest and Oliver (32) (Fig. 1C) and the area of origin of the colliculoolivary projection and the



terminal areas of the corticofugal fibers (Fig. 1A), it is obvious that this scheme is not more suitable concerning the borders of these areas.

It is possible that the difficulties concerning the borders between the external cortex and the central nucleus reflect a gradual change in the cell population on the border between the two subdivisions. Small cells with spheric dendritic trees are located in the central nucleus and in the external cortex. In fact no clear-cut border exists between the central nucleus and the dorsal cortex either: there is a gradual thinning in the border area towards the dorsal cortex where one cell may have dendrites both stretching into the central nucleus and the dorsal cortex.

In this connection the conception of Stiebler and Ehret (42) is of considerable interest. According to their neurophysiological studies most of IC consists of isofrequent laminae curved in different directions. The central part of each lamina has a low stimulus threshold, and stacked upon each other constitute an area slightly smaller than the central nucleus in rat, but resembling the latter in form and localization (Fig. 1D). The laminae in the central nucleus may represent a stricter tonotopical part of larger laminae also including the cortical areas.

The lamination in the central nucleus is due to a parallel organization of afferent fibers as well as neurons with flat dendritic arborization (31). Even if the laminar organization of the afferent fibers was the same within the entire IC, the more spherical form of the dendritic arborization in the cortical areas would contribute to a more pronounced convergence of frequencies on to a single cell. This would be in agreement with the poorer frequency discrimination (4) and the higher threshold

for pure tone stimulation (42) of the cortical areas compared to the central nucleus.

#### GENERAL DISCUSSION

The findings in the three papers are consistent with the existence of a three neuronal chain from the auditory cortex, via the external cortex of the ipsilateral IC, and the periolivary region of the ipsilateral superior olivary complex to the outer hair cells in cochlea and/or cells in the cochlear nuclei (Fig.2). Both these projections terminate on the opposite side. Electronmicroscopical demonstration of the synapses however, remains.

Many people have been speculating about the functional significance of the different parts of IC. According to Adams's (1) HRP studies in cat, IC receives ascending fibers from 24 different kind of cells, of which most project to the central nucleus. According to the present findings (19) this nucleus might participate in feed-back circuits involving the cochlear nuclei. On the other hand the neocortical input to IC is limited to the cortical areas. These areas probably receive much of their ascending auditory information indirectly via the central nucleus (48). The external cortex, because of its electrophysiological qualities and connections, is seen as a center for auditory reflexes (5, 48). It is therefore interesting that the main part of the colliculoolivary fibers originate from here. Because the external cortex also receives fibers from the dorsal column nuclei (7, 46) and from the sensory trigeminal nuclei (47, 48), interaction between auditory and somatosensory systems might take place here. Reflexes originating in this part of IC could therefore be influenced by multisensory impulses.

Auditory reflexes might from their effect be of several kinds. One kind provokes movement of the auricle (pinna), the head or the entire body in the direction of the sound. Another kind of acoustic reflex may be part of a general arousal, a complex reflex that can be provoked by sound via unknown pathways. The external cortex of IC may be involved due to connections with the medial part of the medial geniculate body, and from here to hypothalamus and amygdala and striatum (28).

Eventually there are reflexes whose efferent part affect structures in cochlea itself, the olivocochlear system and the middle ear reflexes are among these. The mentioned systems at the same time overlap and supply each other functionally. Both systems protect the inner hair cells against noise damage (10, 17), the middle ear reflexes by regulating the sound transmission through the ossicles and by this reducing the stimulation of the cochlea. The crossed olivocochlear system affects the outer haircells and by that reduces the cochlear response to the sound. The middle ear reflexes work in the low frequency area and the crossed olivocochlear system mainly in the high frequency area (23).

The olivocochlear system. In the organ of Corti there are two types of hair cells, outer and inner. These are different both by structure and function. The outer hair cells have a modest afferent and rich efferent innervation (4). The inner hair cells have a rich afferent and modest efferent innervation.

The efferent fibers to the inner hair cells originate in the small olivocochlear cells (22, 23) which in rat are located in the lateral superior olive ipsilaterally (45, 35). No fibers from IC were found to project to this nucleus (19). What kind of effect these uncrossed olivocochlear fibers could have, is unknown and will therefore not be discussed here.

The efferent fibers to the outer hair cells origin in the large olivocochlear cells which in rat are located in a restricted area of the periolivary region, preferentially on the opposite side, exactly overlapping the terminal area of the colliculoolivary fibers. These cells have been compared to motoneurons which by influencing the form of the outer hair cells (11), and the stiffness of their stereocilia (43), modulate the sensitivity and "tuning" of the hair cells,(11). If the colliculoolivary neurons have synaptic contact with neocortical fibers on one side and the large olivocochlear cells on the other side, their influence might be under direct neocortical controle. The reason why the inner hair cells are more easily damaged by noise after removal of the outer hair cells, may be the lack of such a centrally dependent inhibition (17).

The dendrites of the large olivocochlear cells are long and oriented perpendicular on the fiber direction in the trapezoid body. As suggested by Guinan et al (23) there is little reason to expect them to be frequent specific. The majority of the colliculoolivary neurons are however localized in the ventral, high frequency part of IC, and this is in line with the fact that the crossed olivocochlear fibers mainly project to the high frequency part of cochlea (22, 23).

The middle ear reflexes. The two middle ear reflexes, the stapedius and the tensor tympani reflex function in almost the same way. They both are provoked by loud noise and by that increase the dynamic area of the ear (9). In human being the tensor tympani reflex is also provoked as a part of a general muscle tension (16). The reflexes both are crossed and uncrossed, but the reflex arches are only partly known. The most thorough anatomical investigation has been done in rabbit by Borg (8). He found that the reflex arches must include the central part of the

ventral cochlear nucleus, the trapezoid body, the medial part of the superior olivary complex, and the facial and trigeminal motor nuclei. These nuclei innervate the stapedial and tensor tympani muscles and in cat lie between the superior olivary complex and the facial nucleus (30, 26), and ventrolateral to the main part of the motor trigeminal nucleus (29), respectively.

According to Borg (8) it is the medial superior olivary complex or the medial periolivary cells that connect the motor nuclei to the superior olivary complex. The present findings gave no clues for such projections, but the material was not quite fit for this kind of investigation (19).

By anterograde and retrograde WGA-HRP studies Itoh et al (25) demonstrated a bilateral projection both from the ventral and dorsal cochlear nuclei to the motor neurons of the m. tensor tympany by anterograde and retrograde WGA-HRP studies. By a closer examination of the present sections (19) with WGA-HRP injections in the dorsal and the posteroventral cochlear nuclei, one might demonstrate a corresponding projection to the trigeminal nucleus also in rat.

The fact that the middle ear reflexes occur before an expected sound stimulus (16), it is reason to believe that the reflex arches have connections from neocortex. This is not contradicted by the fact that the reflexes in Borg's (8) experiments were unaffected by lesions in IC or in the cerebral cortex. It is reasonable to anticipate that the neocortical controle is mediated via descending projections from the part of IC which receives neocortical fibers, the external cortex. With an indirect projection from the external cortex to the motor nuclei via the superior olivary complex, it would be interesting to see if the terminal area of the colliculoolivary fibers also contained neurons with such a projection. This is probable,

because cells connected with the facial nucleus, according to Borg (8) are localized in this very area, in the medial periolivary region.

IC also could project directly to the motor nuclei. After lesions of IC terminal degeneration was found in the areas which probably contain stapedial and tensor tympani neurons (19). Because of accidental lesions of other structures these findings are not conclusive. Further light- and electronmicroscopical studies with specific labelling of the various components are necessary to obtain more precise information around these important reflex arches.

#### References

- 1 Adams, J.C.: Ascending projections to the inferior colliculus. *J Comp Neurol* 183: 519-538, 1979.
- 2 Adams, J.C.: Crossed and descending projections to the inferior colliculus. *Neurosci Lett* 19: 1-5, 1980.
- 3 Adams, J.C.: Cytology of periolivary cells and the organization of their projections in the cat. *J Comp Neurol* 215: 275-289, 1983.
- 4 Aitkin, L.M., Webster, W.R., Veale, J.L. & Crosby, D. C.: Inferior colliculus. I. Comparison of response properties of neurons in central, pericentral and external nuclei of adult cat. *J Neurophysiol* 38: 1196-1207, 1975.
- 5 Aitkin, L.M., Irving, D. R., & Webster, W. R.: Central neural mechanism of hearing. In: Brockhart, J. M., Mountcastle, V. B., Darian-Smith, I. & Geiger, S. R. (eds) *Handbook of Physiology- The Nervous System, Vol 3, part 2*. Waverly Press Inc., Baltimore MD, 1984.
- 6 Andersen, R.A., Snyder, R.L. & Merzenich, M.M.: The topographic organization of corticocollicular projections from physiologically identified loci in the AI, AII and anterior auditory cortical fields of the cat. *J Comp Neurol* 191: 479-494, 1980.
- 7 Bjorkeland, M. & Boivie, J.: An anatomical study of the prejections from the dorsal column nuclei to the midbrain in cat. *Anat Embryol* 170: 29-43, 1984.
- 8 Borg, E.: On the neuronal organization of the acoustic middle ear reflex. A physiological and anatomical study. *Brain Res* 49: 101-123, 1973.

- 9 Borg, E., & Zakrisson, J-E.: Stapedius reflex and speech features. *J Acoust Soc Am* 54(2): 525-527, 1973.
- 10 Borg, E., Nilsson, R. & Liden, G.: Fatigue and recovery of the human acoustic stapedius reflex in industrial noise. *J Acoustic Soc Am* 65,3: 846-848, 1979.
- 11 Brownell, W.E.: Observations on a mobile response in isolated outer hair cells. In: Webster, W.R. & Aitkin, L.M. (eds). *Mechanisms of Hearing*. Monash University Press, Clayton, Victoria, Australia 3168, p5, 1983.
- 12 Cajal, S.Ry.: *Histologie du systeme nerveux de l homme et des vertebres*. A Maloine, Paris, pp 153-173, 1909.
- 13 Caviness, V.S.: Architectonic map of neocortex of the normal mouse. *J Comp Neurol* 164:247-264, 1975.
- 14 Caviness, V.S., & Frost, D.O.: Tangential organization of thalamic projections to the neocortex in the mouse. *J Comp Neurol* 194:335-367, 1980.
- 15 Clerici, W.J. & Coleman, J.R.: Resting and high-frequency evoked 2-deoxyglucose uptake in the rat inferior colliculus: developmental changes and effects of short-term conduction blockade. *Dev Brain Res* 27:127-137, 1986.
- 16 Djupesland, G.: Contractions of the tympanic muscles in man. *Universitetsforlaget, Oslo*. Norwegian monographs on Medical Science, 1967.
- 17 Engstr|m, B.: Stereocilia of sensory cells in normal and hearing impaired ears. A morphological, physiological and behavioural study. *Scand Audiol Suppl* 19:1-34, 1983.
- 18 Faye-Lund, H.: The neocortical projection to the inferior colliculus in the albino rat. *Anat Embryol* 173:53-70, 1985.
- 19 Faye-Lund, H.: Projection from the inferior colliculus to the superior olivary complex in the albino rat. *Anat Embryol* 175:35-52, 1986.
- 20 Faye-Lund, H. & Osen, K.K.: Anatomy of the inferior colliculus in rat. *Anat Embryol* 171:1-20, 1985.
- 21 Geniec, P. & Morest, D.K.: The neuronal architecture of the human posterior colliculus. *Acta Otolaryngol Suppl* 295:1-33, 1971.
- 22 Guinan, J.J., Warr, W. B. & Norris, B.E.: Differential olivocochlear projections from lateral versus medial zones of the superior olivary complex. *J Comp Neurol* 221: 358-370, 1983.
- 23 Guinan, J. J., Warr, W.B. & Norris, B. E.: Topographic organization of the olivocochlear projections from the lateral and medial zones of the superior olivary complex. *J Comp Neurol* 226:21-27, 1984.

- 24 Hashikawa, T.: The inferior colliculopontine neurons of the cat in relation to other collicular descending neurons. *J Comp Neurol* 219:241-249, 1983.
- 25 Itoh, K., Nomura, S., Konishi, A., Yasui, Y., Sugimoto, T. & Muzino, N.: A morphological evidence of direct connections from the cochlear nuclei to tensor tympani motoneurons in the cat: a possible afferent limb of the acoustic middle ear reflex pathways. *Brain Res* 375:214-219, 1986.
- 26 Joseph, M.P., Guinan, J.J., Fullerton, B.C., Norris, B.E. & Kiang, N.Y.S.: Number and distribution of stapedius motoneurons in cats. *J Comp Neurol* 232:43-54, 1985.
- 27 Krieg, W.J.S.: Connections of the cerebral cortex. I. The albino rat. A topography of the cortical areas. *J Comp Neurol* 84:221-276, 1946.
- 28 LeDoux, J.E., Ruggiero, D.A. & Reis, D.J.: Projections to the subcortical forebrain from anatomically defined regions of the medial geniculate body in the rat. *J Comp Neurol* 242:182-213, 1985.
- 29 Lyon, M.J.: Localization of the efferent neurons of the tensor tympany muscle of the newborn kitten using horseradish peroxidase. *Exp Neurol* 49:439-455, 1975.
- 30 Lyon, M.J.: The central location of the motor neurons to the stapedius muscle in the cat. *Brain Res* 143:437-444, 1978.
- 31 Morest, D.K.: The laminar structure of the inferior colliculus of the cat. *Anat Rec* 148:314, 1964.
- 32 Morest, D.K. & Oliver, D.L.: The neuronal architecture of the inferior colliculus in the cat: Defining the functional anatomy of the auditory midbrain. *J Comp Neurol* 222:209-236, 1984.
- 33 Noort, J.van: The structure and connections of the inferior colliculus. An investigation of the lower auditory system. *Proefschrift, van Gorcum & Comp, NV Leiden*, pp 1-118, 1969.
- 34 Osen, K.K. & Roth, K.: Histochemical localization of cholinesterases in the cochlear nuclei of the cat, with notes on the origin of acetylcholinesterase-positive afferents and the superior olive. *Brain Res* 16:165-185, 1969.
- 35 Osen, K.K., Mugnaini, E., Dahl, A-L. & Christiansen, A.H.: Histochemical localization of acetylcholinesterase in the cochlear and the superior olivary nuclei. A reappraisal with emphasis on the cochlear granule cell system. *Arch Ital Biol* 122:169-212, 1984.



- 36 Paxinos, G. & Watson, C.: The rat brain in stereotaxic coordinates. Academic Press, Sydney, New York, London, pp 1-12, 1982.
- 37 Rasmussen, G.L.: The olivary peduncle and other fiber projections of the superior olivary complex. *J Comp Neurol* 84:141-220, 1946.
- 38 Rockel, A.J. & Jones, E.G.: The neuronal organization of the inferior colliculus of the adult cat. I. The central nucleus. *J Comp Neurol* 147:11-60, 1973a.
- 39 Rockel, A.J. & Jones, E.G.: The neuronal organization of the inferior colliculus of the adult cat. II. The pericentral nucleus. *J Comp Neurol* 149:301-334, 1973b.
- 40 Ryugo, D.K. & Killackey, H.P.: The neuronal organization and efferent connections of the inferior colliculus of the rat. *Soc Neurosci Abstr* 40:30, 1975.
- 41 Spoenclin, H.: The afferent innervation of the cochlea. In: Naunton, R.F. & Fernandez, L.(eds). Evoked electrical activity in the auditory nervous system. Academic Press, New York, San Fransisco, London. pp 21-41, 1978.
- 42 Stiebler, I. & Ehret, G.: Inferior colliculus of the House mouse. I. A quantitative study of tonotopic organization, frequency representation, and tone-threshold distribution. *J Comp Neurol* 238:65-76, 1985.
- 43 Strelieff, D. & Flock, J.: Mechanical properties of hair bundles of receptor cells in the guinea pig cochlea. *Soc Neurosci Abstr* 5:40, 1982.
- 44 Warr, W.B.: Olivocochlear and vestibular efferent neurons of the number determined by retrograde axonal transport and acetylcholinesterase histochemistry. *J Comp Neurol* 161:159-182, 1975.
- 45 White, J.S. & Warr, W.B.: The dual origins of the olivocochlear bundle in the albino rat. *J Comp Neurol* 219:203-214, 1983.
- 46 Wiberg, M. & Blomqvist, A.: The projection to the mesencephalon from the dorsal column nuclei. An anatomical study in the cat. *Brain Res* 311:225-244, 1984.
- 47 Willard, F.H. & Ryugo, D.K.: External nucleus of the inferior colliculus: A site of overlap for ascending auditory and somatosensory projections in the mouse. *Soc Neurosci Abst* 5:33, 1979.
- 48 Willard, F.H. & Ryugo, D.K.: Anatomy of the central auditory system. In: Willot, J.F.(ed). The auditory Psychobiology of the mouse. Thomas, C.C., Springfield Ill., pp 201-304, 1983.