

Large Section Cryomicrotomy: A Basic Method for Microdissectioning and *in vitro* Autoradiography of Human Nervous Tissue

Sten-Magnus Aquilonius

Department of Neurology, University Hospital, S-751 85 Uppsala, Sweden

1. INTRODUCTION

Evolution of the important technique of whole body autoradiography of experimental animals, introduced by Ullberg in 1954, has been directly linked to the development of heavy-duty cryomicrotomes (16). Since then, large-section cryomicrotomy has found several new areas of application. The present paper will illustrate the usefulness of this basic methodology as exemplified by studies in our own research group.

Reports including technical details have recently been published (5, 10).

2. TOPOGRAPHICAL ANATOMY OF HUMAN BRAIN AND MUSCLE

2.1 Brain

Computed tomography (CT) is established as a most important technique in neuroradiology. CT of the brain is mainly restricted to near horizontal planes, a fact which creates a need for anatomical knowledge of brain sections which were not commonly studied previously. Therefore, we applied large section cryomicrotomy of whole human brain and produced a colour atlas of horizontal cryosections (Fig. 1 A) which were photographed just thawed against a black background (3).

However, this atlas does not illustrate the relationship between brain and surrounding tissues. A head-brain atlas based on the technical modifications of cryomicrotomy worked out by Rauschnig (this volume) would be a useful complement to the neuroimaging techniques, CT, nuclear magnetic resonance, and positron emission tomography.

2.2 Muscle

Knowledge about the topographical distribution of motor endplates in human muscle is important both for the neurophysiolo-

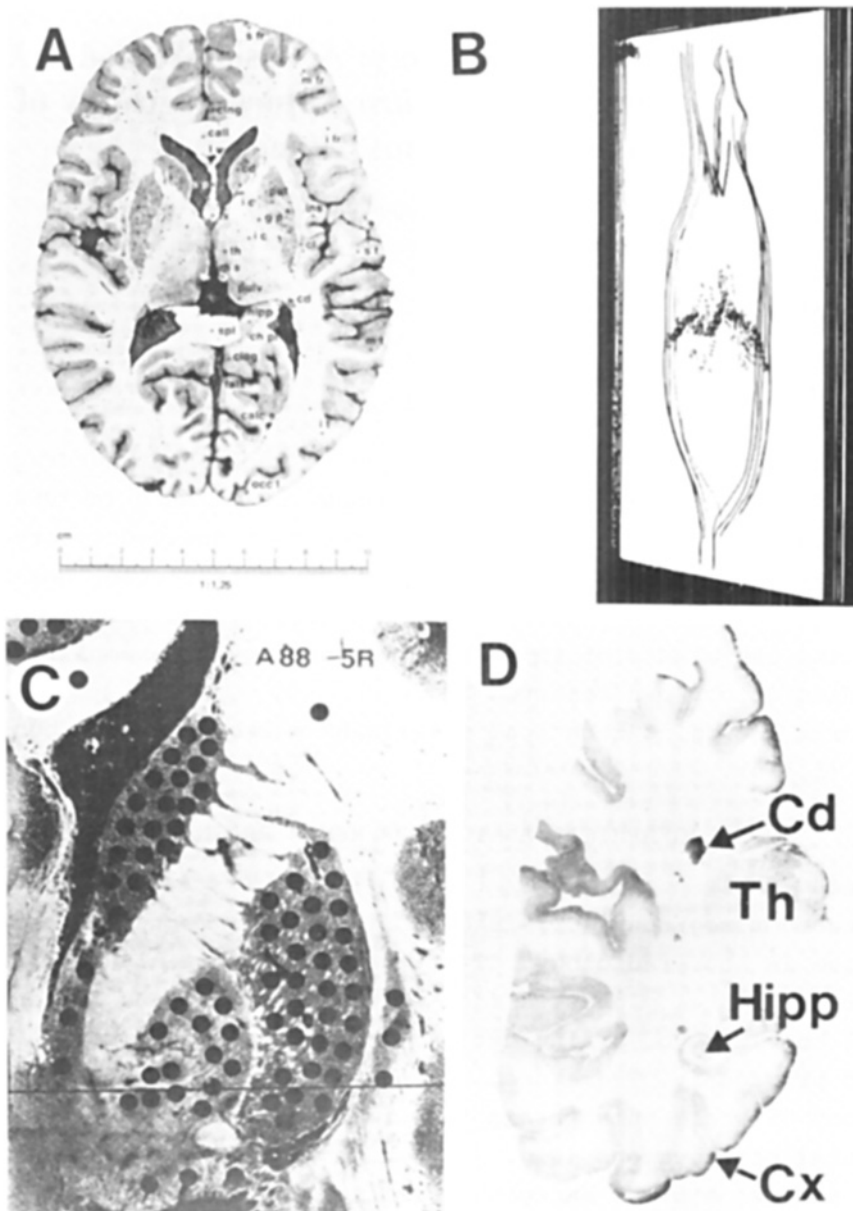


Fig. 1 Different applications of large section cryomicrotomy: A) Topographical atlas of the human brain (4) adapted to computed tomography. B) Distribution of ChE staining in whole human biceps muscle (5). C) Tissue punches within a section through extrapyramidal structures 5 mm behind the anterior commissure (8). D) In vitro autoradiography in a frontal section of a human hemisphere (3) using the muscarinic ligand ^3H -QNB.

gist carrying out electromyography and for the clinician taking a muscle biopsy. However, due to technical difficulties at sectioning, available information was based on cholinesterase (ChE) staining of muscles from small children only. By means of the heavy-duty cryomicrotome (PMV 400, LKB 2250, LKB, Sweden) it is possible to obtain horizontal cryosections of adult whole human muscle. We have studied the distribution of motor end-plates in biceps brachii (Fig. 1 B), tibialis anterior and sartorius muscle from adults by staining longitudinal cryosections of the whole muscles for ChE (5). The results from a large number of cryosections from biceps brachii and tibialis anterior muscles were analysed by a computer to reconstruct the topographical end-plate distribution within the whole muscle (2).

3. THE "PUNCH-TECHNIQUE" OF TISSUE SAMPLING FROM CRYOSECTIONS OF HUMAN BRAIN AND SPINAL CORD

A defined and reproducible method of tissue dissectioning is a prerequisite for regional neurochemical studies in post-mortem nervous tissue. For this purpose the "punch-technique" of tissue sampling has been rather extensively used in animal (see 14 for review) and human studies (see 5 for review).

We introduced this technique (Fig. 1 C) in an investigation on the regional distribution of choline acetyltransferase (ChAT) within the brain of controls and Huntington chorea cases (6). Thereby, it was possible to obtain the most detailed localization of human brain ChAT available at that time and to demonstrate the marked reduction of neostriatal ChAT in Huntington's disease, probably corresponding to a pronounced degeneration of cholinergic interneurons.

More recently the "punch-technique" of microdissectioning has been used in investigations on the topical localization of ChAT within the human spinal cord (4). In addition to an area of high activity in the ventrolateral part of the ventral horn traced into the ventral root region and probably corresponding to motor neurons, another area of high ChAT activity was found in the apical part of the dorsal horn. In motor neuron disease the reductions in spinal ChAT are not restricted to the motor neuron areas (9) indicating a more general involvement of cholinergic structures.

In view of the rapid development and application in human post-mortem tissue of immunohistochemical methods for the localization of neurotransmitter systems tissue sampling by methods

like the "punch-technique" might be of less importance in the future. However, biochemical analysis of enzyme activities within well defined tissue specimens will still represent an important complementary technique especially in quantitative investigations.

4. LARGE SECTION CRYOMICROTOMY FOR IN VIVO RECEPTOR AUTORADIOGRAPHY

In recent years in vitro autoradiographic techniques (17) have been extensively employed for localization of receptor sites within different tissues. So far, the methods have mainly been applied to rather small sections, like in our own studies, the spinal cord (8, 11). However, technical modifications have now been worked out permitting in vitro autoradiographic studies in very large tissue sections (10).

4. 1 Muscle

After freezing whole human biceps brachii muscles between metal plates and horizontal cryosectioning, in vitro receptor autoradiography using ^3H -alpha-bungartoxin (^3H -alpha-Btx) as ligand for the nicotinic cholinergic receptors has been performed (7). It could be demonstrated that in motor neuron disease ^3H -alpha-Btx binding occurred over the entire muscle, indicating uncovering of extrajunctional sites while in the control the binding was restricted to the motor end-plate region.

4. 2 Brain

In the last years the development of large section in vitro receptor autoradiography (Fig. 1 D) has enabled studies on regional distribution as well as quantitation of different receptor sites within the whole human brain (12, 15, see 13 for review). Such studies represent important complements to in vivo receptor autoradiographic studies in man by positron emission tomography. Of special interest in this connection is the possibility to perform in vitro large section autoradiography on post-mortem brain sections in parallel to positron emission tomography using the same ^{11}C -labelled ligand. Such studies have recently been carried out in our laboratories using a benzodiazepine receptor ligand (d'Argy et al to be published).

5. CONCLUSIONS

In clinical neuroscience large section cryomicrotomy has found valuable applications in topographical neuroanatomy and as a tool in microdissection of tissue for neurochemical analysis. Recently,

cryomicrotomy-in vitro-autoradiography has been introduced as a most important technique for the localization of neuroreceptors and provides a useful complement to human in vivo studies by positron emission tomography.

REFERENCES

1. Aquilonius, S.-M., Arvidson, B., Askmark, H. & Gillberg, P.-G.: Topographical localization of end-plates in cryosections of whole human biceps muscle. *Muscle Nerve* 5:418, 1982.
2. Aquilonius, S.-M., Askmark, H., Gillberg, P.-G., Nandedkar, S., Olsson, Y. & Stålberg, E.: Topographical localization of motor endplates in cryosections of whole human muscles. *Muscle Nerve* 7:287-293, 1984.
3. Aquilonius, S.-M. & Eckernäs, S.-Å.: A colour atlas of the human brain adapted to computed tomography. Esselte Studium, Stockholm, 1980.
4. Aquilonius, S.-M., Eckernäs, S.-Å. & Gillberg, P.-G.: Topographical localization of choline acetyltransferase within the human spinal cord and a comparison with some other species. *Brain Res* 211:329-340, 1981.
5. Aquilonius, S.-M., Eckernäs, S.-Å. & Gillberg, P.-G.: Large section cryomicrotomy in human neuroanatomy and neurochemistry. In: *Brain Microdissection Techniques* (ed. A.C. Cuellar), pp. 165-170. John Wiley & Sons, Chichester, 1983.
6. Aquilonius, S.-M., Eckernäs, S.-Å. & Sundwall, A.: Regional distribution of choline acetyltransferase in the human brain: Changes in Huntington's chorea. *J Neurol Neurosurg Psychiat* 38:669-677, 1975.
7. Askmark, H., Gillberg, P.-G. & Aquilonius, S.-M.: Autoradiographic visualization of extrajunctional acetylcholine receptors in whole human biceps brachii muscle. Changes in amyotrophic lateral sclerosis. *Acta Neurol Scand* 72:344-347, 1985.
8. Gillberg, P.-G. & Aquilonius, S.-M.: Cholinergic, opioid and glycine receptor binding sites localized in human spinal cord by in vitro autoradiography. *Acta Neurol Scand* 72:299-306, 1985.
9. Gillberg, P.-G., Aquilonius, S.-M., Eckernäs, S.-Å., Lundqvist, G. & Winblad, B.: Choline acetyltransferase and substance P-like immunoreactivity in the human spinal cord: changes in amyotrophic lateral sclerosis. *Brain Res* 250:394-397, 1982.
10. Gillberg, P.-G., Jossan, S.S., Askmark, H. & Aquilonius, S.-M.: Large-section cryomicrotomy for in vitro receptor autoradiography. *J Pharmacol Methods* 15:169-180, 1986.
11. Gillberg, P.-G., Nordberg, A. & Aquilonius, S.-M.: Muscarinic binding sites in small homogenates and in autoradiographic sections from rat and human spinal cord. *Brain Res* 300:327-333, 1984.
12. Johnston, M.V., Silverstein, F.S., Reindel, F.O., Penney, J.B. Jr. & Young, A.B.: Muscarinic cholinergic receptors in human infant forebrain: ³H-quinuclidinyl benzilate binding in homogenates and quantitative autoradiography in sections. *Dev Brain Res* 19:195-203, 1985.
13. Palacios, J.M., Probst, A. & Cortés, R.: Mapping receptors in the human brain. *TINS* 6:284-289, 1986.
14. Palkovits, M. & Brownstein, M.J.: Microdissection of brain areas by the punch technique. In: *Brain Microdissection Techniques* (ed. A.C. Cuellar), pp. 1-36. John Wiley & Sons,

- Chichester, 1983.
15. Penney, J.B. & Young, A.B.: Quantitative autoradiography of neurotransmitter receptors in Huntington's disease. *Neurology* 32:1391-1395, 1982.
 16. Ullberg, S.: The technique of whole body autoradiography. Cryosectioning of large specimens. *Science Tools, The LKB Instrumental Journal, Special Issue 2-23*, 1977.
 17. Young, W.S. & Kuhar, M.J.: A new method for receptor autoradiography: ^3H -opioid receptors in rat brain. *Brain Res* 179: 255-270, 1979.

Address for reprints:

Sten-Magnus Aquilonius
Department of Neurology
University Hospital
S-751 85 Uppsala

SWEDEN