

Primary Hyperoxaluria (Glycolic Acid Variant)

A Clinical and Genetical Investigation of Eight Cases

GÖSTA HOLMGREN, THOMAS HÖRNSTRÖM, STIG JOHANSSON
and GÖSTA SAMUELSON

From the Department of Pediatrics, University Hospital, Umeå and the Department of Clinical Chemistry, Karolinska sjukhuset, Stockholm, Sweden

ABSTRACT

The clinical features of eight cases of primary hyperoxaluria have been summarized. The possibility of different phenotypes is discussed. A reduction, but no normalization, of the oxalate formation during pyridoxine therapy was found. A renal transplantation performed in one of the patients failed because of the formation of nephrocalcinosis.

INTRODUCTION

The first description of primary hyperoxaluria was that by Lepoutre in 1925 (13), but it was not until the early 1950's that the clinical and pathological entity was accurately characterized (1, 6). In 1964, data on 63 typical cases, and 42 atypical cases were summarized in a review (11). Another 24 patients with the disease were presented in 1968 (16).

In Sweden hyperoxaluria is a rare disease. Only one family has hitherto been published by Öigaard et al. 1957 and 1963 (19, 20). They reported a family with hyperoxaluria in the father and four children, who all died from the disease (Table I).

The aim of the present study was to present a clinical and genetical investigation in another eight Swedish cases of primary hyperoxaluria with different clinical entities (cf. Table II).

METHODS

Urine was collected in bottles with hydrochloric acid to a final acidity corresponding to 0.1 M HCl. Determination of oxalic and glyoxylic acid in urine and oxalic acid in serum was performed according to Zarembski & Hodgkinson (17, 18).

Glycolic acid in urine was determined by the method described by Calkins (3).

Our normal values are, for oxalic acid in urine 0.93–5.53 mmol/24 h, for glyoxylic acid in urine 0.093–0.639 mmol/24 h, for glycolic acid in urine 1.46–5.92 mmol/24 h

and for oxalic acid in serum 20.2–32.10 $\mu\text{mol/l}$. These values are in good agreement with corresponding values described in the literature (11).

The analytical error determined from the differences (D) between double determinations according to the formula: $\pm \Sigma D^2/2N$ and expressed as $\mu\text{mol/ml}$ was for oxalic acid 0.49 $\mu\text{mol/ml}$, for glycolic acid 0.25 $\mu\text{mol/ml}$ and for glyoxylic acid 0.04 $\mu\text{mol/ml}$.

RESULTS

The results of the laboratory analyses, concerning oxalic, glycolic and glyoxylic acid are presented in Table III.

CASE REPORTS

The index case was a 6-year-old boy with haematuria and kidney stone symptoms. A familial study was performed and another two cases of hyperoxaluria were detected (Fig. 1 and Table II). Two other cases were brothers with no relations to the former family. The last three cases of hyperoxaluria were sporadic, collected from different parts of Sweden.

Case 1, D. G. 61 07 18

A boy, the second out of three siblings, related to the cases 2 and 3, cf. Fig. 1. The parents were healthy. Several other family members were suffering from kidney stone symptoms.

Early history and physical examination were normal.

Admitted at the age of 4 years, because of haematuria, and attacks of renal colic.

Routine laboratory analysis of blood was normal. Repeated analysis of plasma calcium and phosphate were within normal limits. Urinary laboratory examination revealed a microscopic haematuria. No proteinuria. Increased urinary excretion of oxalic, glycolic and glyoxylic acid was seen on several occasions (cf. Table III). The osmolar concentration of 24-hour urine sample was 480 mOsm/l after pitressin. Endogen creatinine clearance 68 ml/min/1.73 m² body surface. The urinary pH was 5.1 after sodium bicarbonate intake.

Table I. Clinical and familial data on five cases of hyperoxaluria published in Sweden in 1963 (19, 20)

| Case | Born in year | Sex | Age in years at onset | Dead (d) | Family history | | Renal calculi | Nephrocalcinosis | Extra-renal oxalate |
|------|--------------|----------------|-----------------------|----------|----------------|-----------|---------------|------------------|---------------------|
| | | | | | Siblings | Others | | | |
| 1 | 1895 | M (father) | 30 | d (70) | — | + (child) | + | + | — |
| 2 | 1923 | M | 25 | d (25) | + | — | + | + | + |
| 3 | 1925 | M | 26 | d (49) | + | — | + | + | — |
| 4 | 1933 | M | 17 | d (17) | + | — | + | + | — |
| 5 | 1928 | F ^a | 13 | d (13) | + | — | — | — | — |

^a Died in uraemia. X-ray examination was not performed.

Table II. Clinical and familial data on eight new cases of hyperoxaluria in Sweden 1977

n.c.s. = no clinical symptoms

| Case | Born in year | Sex | Age in years at onset | Dead (d), alive (a) | Family history | | Renal calculi | Nephrocalcinosis | Extra-renal oxalate |
|--------------|--------------|-----|-----------------------|---------------------|-----------------------|--------|---------------|------------------|---------------------|
| | | | | | Siblings | Others | | | |
| 1 (D. G.) | 1961 | M | 4 | a | — | + | + | + | — |
| 2 (F. J.) | 1928 | M | 22 | a | — | + | + | + | — |
| 3 (B. J.) | 1955 | M | n.c.s. | a | — | + | — | — | — |
| 4 (M. T.-F.) | 1937 | M | | a | Haematuria in 4 sibs. | — | + | — | — |
| 5 (L. W.) | 1952 | M | 13 | a | + | — | + | + | — |
| 6 (J. W.) | 1950 | M | 10 | d (18) | + | — | + | + | — |
| 7 (I. U.) | 1966 | F | 2 | d (7) | — | — | + | + | + |
| 8 (U. A.) | 1967 | F | 2/12 | d (8/12) | — | — | + | + | + |

Intravenous pyelography revealed nephrocalcinosis.

The boy onwards suffered from abdominal pain probably caused by attacks of renal colic about 3–4 times a year. On several occasions renal calculi were noticed in the urine. A therapeutic trial during the years 1968–1977 with pyridoxine, 5–7 mg per kg body weight and magnesium oxide 300–500 mg a day, did not influence with certainty on the frequency of attacks of renal colic. The mean urinary excretion of oxalic acid, and to a certain degree of glycolic acid, was lowered but not normalized during this treatment, Table IV.

At the age of 11 years a progress of the nephrocalcinosis was shown by the X-ray examinations. At the age of 15 years no further progress of the nephrocalcinosis was shown by X-ray. Plasma creatinine was 90 $\mu\text{mol/l}$. The osmolar concentration after 12 hours' thirst was 472 mOsm/l, and the endogen creatinine clearance was 90 ml/min/1.73 m².

Case 2, F. J. 28 12 19

A male, the youngest of ten siblings, the father of case 3 (B. J.). Several relatives had had attacks of renal colic, cf. Fig. 1.

Early history and physical examination were normal. Admitted at the age of 22 years because of abdominal pains, diagnosed as an attack of renal colic by intravenous pyelography which showed nephrolithiasis. Onwards he had quite few symptoms until the age of 37, when he was readmitted to hospital because of several attacks of renal

colic that necessitated bilateral pyelotomies and ureterotomies. Routine laboratory examination of blood was normal. Plasma calcium and phosphate concentrations were normal. Creatinine in serum 117 $\mu\text{mol/l}$. Routine urinalysis revealed no abnormal findings. Urinary pH was 7.0.

Intravenous pyelography at the ages 46 and 49 years showed normal findings. Increased urinary excretion of oxalic and glyoxylic acids was seen, Table III.

Case 3, B. J. 55 12 24

A boy, the only child of case 2 (F. J.). Several relatives had suffered from attacks of renal colic, cf. Fig. 1.

Early history and physical examination were normal.

Admitted without symptoms at the age of 15 years due to a family investigation of case 2.

Routine laboratory examinations of blood and urine were normal as well as intravenous pyelography. The osmolar concentration of 24-hour urine sample was normal. Plasma creatinine was 70 $\mu\text{mol/l}$. Increased urinary excretion of oxalic and glyoxylic acids was seen (cf. Table III).

Case 4, M. T.-F. 37 10 23

A male, number four of seven siblings, consanguinity was traced in the parents. Frequent attacks of haematuria and bacteriuria were seen in the mother, three sisters and in a half-sister. His youngest brother has often suffered from ureteral stone attacks. However, the urinary excretion of

Table III. Serum oxalic acid concentration and urinary excretion of oxalic, glycolic and glyoxylic acid in cases 1–8

| Case | S-oxalic acid ($\mu\text{mol/l}$) | U-oxalic acid (mmol/24 h) | U-glycolic acid (mmol/24 h) | U-glyoxylic acid (mmol/24 h) |
|------------------------|--|------------------------------|--------------------------------|---------------------------------|
| 1 (D. G.) | – | 22.21 | 10.98 | 1.04 |
| 2 (F. J.) | – | 9.77 | 5.39 | 1.11 |
| 3 (B. J.) | – | 11.33 | 4.21 | 0.94 |
| 4 (M. T.-F.) | – | 9.44 | 6.97 | 0.94 |
| 5 (L. W.) | – | 20.21 | 21.04 | 0.54 |
| 6 (J. W.) ^a | 37.31–243.20 | – | – | – |
| 7 (I. U.) | – | 10.33 | 10.98 | 0.54 |
| 8 (U. A.) ^b | – | 24.54 | 29.19 | 4.05 |
| Normal values | 20.2–32.1 | 0.93–5.53 | 1.46–5.92 | 0.093–0.639 |

^a As this patient was anuric, only serum values are given.

^b As the 24-hour volume was unknown, the values were given in mmol/g creatinine. These values are higher than those observed in children of the same age.

oxalic acid, glycolic acid and glyoxalate was normal in these individuals.

Early history and physical examination were normal.

Since the age of 26 years he had suffered from attacks of renal colic. Transparent quartzlike concretions were observed at 12–13 events.

Admitted to the hospital at the age of 28 years.

Routine laboratory examinations of blood and urine were normal. The urinary excretion of oxalic, glycolic and glyoxylic acids was increased at several occasions (Table III). The osmolar concentration of 24-hour urine sample was normal. Plasma creatinine was 100 $\mu\text{mol/l}$. The urinary pH was 5.5.

Intravenous pyelography showed renal calculi.

Still at the age of 40 years plasma creatine as well as other renal function tests were about normal, and no nephrocalcinosis was seen at intravenous pyelography.

Case 5, L. W. 52 10 10

A male, number two out of four siblings. His mother died of a renal disease of unknown etiology. His elder brother is case 6.

Early history and physical examination were normal.

Admitted at the age of 13 years. Intravenous pyelography showed bilateral ureteral stones and a unilateral pyelolithotomia was performed. The stone consisted of calciumoxalate-monohydrate. Readmitted at the age of 16 years for verification of the suspected diagnosis hyperoxaluria.

Routine laboratory examinations of blood and repeated analysis of plasma calcium and phosphate were within normal limits. Increased urinary excretion of oxalic, and glycolic acids was seen (cf. Table III).

Renal function tested by the inulin and the PAH-clearances indicated a slight reduction in the glomerular and the tubular functions. The osmolar concentration after 12 hours' thirst was 472 mOsm/l, and the maximum concentration after pitressin of 610 mOsm/l. Endogen creatinine clearance was 102 ml/min. Plasma creatinine 72 $\mu\text{mol/l}$.

A therapeutic trial during a 5-year period with pyridoxine 200–400 mg orally per day reduced significantly the excretion of oxalic acid, and no further progress of the nephrocalcinosis was seen by the X-ray examinations.

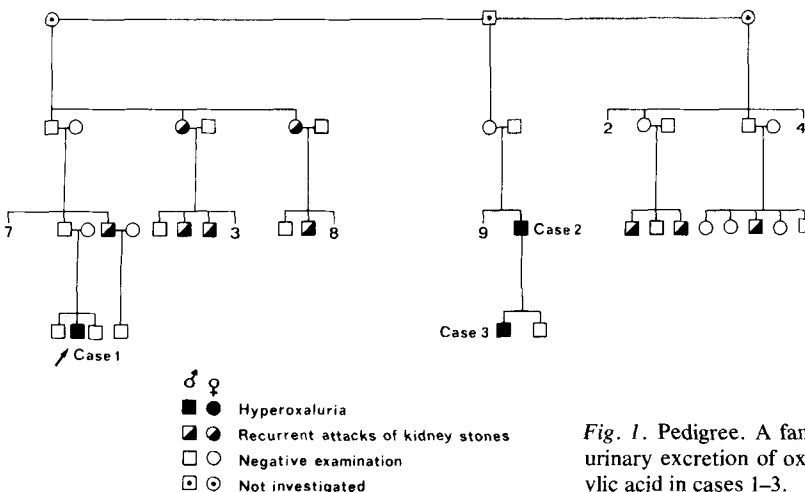


Fig. 1. Pedigree. A familial investigation concerning the urinary excretion of oxalic acid, glycolic acid and glyoxylic acid in cases 1–3.

Table IV. The urinary excretion of oxalic acid, glycolic and glyoxylic acids/24 h in case 1, before and during B₆ therapy

| No. of examinations | Oxalic acid (mmol/24 h) | Glycolic acid (mmol/24 h) | Glyoxylic acid (mmol/24 h) |
|---|----------------------------|------------------------------|-------------------------------|
| <i>Before B₆ therapy</i> | | | |
| 4 | 19.99±1.42 | 11.64±1.24 | 0.081±0.041 |
| Range | 11.39–22.31 | 9.97–14.17 | 0.041–0.135 |
| <i>During B₆ therapy (2 years)</i> | | | |
| 36 | 9.44±4.21 | 9.26±3.69 | 0.365±0.230 |
| Range | 1.28–20.06 | 1.87–20.93 | 0.014–1.067 |
| Normal values | 0.93–5.53 | 1.46–5.92 | 0.093–0.639 |

During the last years a further progress of nephrocalcinosis and a deterioration of the renal function tests has been observed resulting in uraemia.

Case 6, J. W. 50 04 22

A male, number three out of four siblings, a younger brother is case 5.

Early history was normal.

Since the age of 7 years he has suffered from sporadic attacks of renal colic. Still at the age of 10 years normal renal function was seen.

Admitted at the age of 18 years because of uraemia and bilateral nephrolithiasis. Intravenous pyelography revealed a nonfunctioning left kidney with several ureteral calculi in a distal position, and several ureteral calculi in the right kidney.

Routine laboratory examinations of blood were normal. Plasma creatinine 160 µmol/l. Standard bicarbonate 14 mmol/l and plasma potassium 5 mmol/l.

After peritoneal dialysis a clinical recovery was seen and a pyelolithotomy could be performed, and several ureteral concretions were removed. One month later, uraemia and electrolyte disturbances resulted in haemodialysis. Shortly later the diagnosis hyperoxaluria was confirmed when increased plasma concentration of oxalic acid was determined at several occasions, Table III.

Later a renal transplantation was performed. Initially a good function was seen in the transplanted kidney but a few months later nephrocalcinosis appeared in the transplanted kidney and the patient died at the age of 19 years in uraemia.

Case 7, I. U. 66 12 07

A female, the eldest out of four siblings. Healthy parents. Maternal grandmother had renal carcinoma and two maternal uncles had attacks of renal colics. The urinary excretion of oxalic and glycolic acid and glyoxylate was within normal limits in these individuals as well as in parents and sibs.

Early history, height and weight as well as psychomotor development were normal.

Admitted at the age of 2½ years because of attacks of renal colics and ureterolithomy was performed because of obstruction of the ureter.

Intravenous pyelography performed at the age of 2½ years revealed renal calcinosis.

Routine laboratory analyses of blood and urine were normal. Serumcalcium was 2.20 mmol/l and serum phosphate 1.5 mmol/l, both of them within normal limits. Serum creatinine was increased to 186 µmol/l (normal values 53–100 µmol/l). Serumurea was also increased to 22.0 mmol/l (normal values 3.6–7.2 mmol/l). Bicarbonate in serum varied from 28.0 to 16.0 mmol/l. Urinalysis revealed urinary tract infection. Signs of rickets were seen on X-ray. The osmolar concentration of urine was 400 mOsm/l after pitressin and the creatinine clearance was 60 ml/min/1.73 m² body surface. Increased urinary excretion of oxalic, and glycolic acid was seen, Table III. Onwards she developed signs of progressive renal insufficiency with renal rickets resulting in fractures. She had also frequent attacks of urinary tract infections necessitating continuous therapy with antibiotics. Since the age of 6 years extrarenal oxalosis was suspected because of hepatomegaly. Height was reduced for her age to 106 cm, –2.5 S.D. There were signs of advanced renal insufficiency with anemia (Hb 80 g/l), renal acidosis with serum bicarbonate 17 mmol/l and increased blood pressure to 155/105. A diet low in protein and sodium as well as antihypertensive medication was instituted.

At the age of seven years she was admitted to hospital because of hypocalcemic tetany. She had further deterioration of the renal function with anemia, hypertension, hepatic and cardiac megaly and pulmonary edema and she died after one month in a circulatory collapse.

At autopsy crystals containing oxalic as well as uric acid were seen in the tubulae, vertebrae, liver, spleen and coronary arteries.

Case 8, U. A. 67 05 18

A girl, the second child of healthy parents. The first child born in 1966, died shortly post partum in asphyxia caused by the umbilical cord around the neck. No cases of kidney diseases were reported in the family.

Early history and early clinical course (birth weight 4 300 g) was uneventful.

Admitted at the age of three months because of poor weight gain. Anaemia and uraemia (plasma creatinine 370 µmol/l) was observed.

A temporary improvement was seen after treating the

patient with corticosteroids and antihypertensive drugs. In a short period, an impairment was seen in the clinical state and a transplantation was planned, but not appropriate donor was found. Peritoneal dialysis was initiated at the age of eight months, but the infant suddenly died in sepsis and bronchopneumonia.

Findings at autopsy revealed bronchopneumonia. The kidneys were enlarged, yellow and with lobated surfaces. The parenchyma was light yellow with a diffuse cortical zone, with signs of pyelitis or cysto-pyelitis. Microscopic examinations of the kidney parenchyma revealed an immense storage of calcium oxalate monohydrate and calcium oxalate dihydrate.

Urinary metabolic screening for amino acids was normal, but a post mortem analysis of the same urinary sample revealed hyperoxaluria (cf. Table III).

DISCUSSION

Although hyperoxaluria was first described in 1925 (13), the familial nature of the disease was first emphasized in 1954 with the report of hyperoxaluria and oxalosis in identical twins, who died of chronic renal failure (14). Primary hyperoxaluria appears to be inherited as an autosomal recessive character according to a number of familial studies (11), although an autosomal dominant mode of inheritance has been proposed (20). In the present study hyperoxaluria was observed in two generations in cases 2 and 3. Whether this can be explained by an autosomal dominant mode of inheritance or not, is open to discussion. In case 1 in this family, however, normal values concerning oxalic acid, glycolic acid and glyoxylic acid were seen in his parents, consequently contradicting the hypothesis of an autosomal dominant mode of inheritance. Cases 5 and 6 were brothers. Their parents and siblings had a normal urinary excretion of oxalic acid, glycolic acid and glyoxylic acid indicating an autosomal recessive mode of inheritance in this family. Cases 4, 7 and 8 were sporadic.

The family histories of cases 1–4 revealed an unexpected high frequency of cases suffering from haematuria and ureteral calculi. This makes us suspect that cases of hyperoxaluria may be missed in screening surveys due to large fluctuations in the urinary excretion of oxalic acid. Such fluctuations have earlier been observed in normals as well as in hyperoxalurics (9). Consequently urinary analysis for oxalic acid should be performed repeatedly in the same individual. The frequency of missed cases of hyperoxaluria due to this reason should be significantly lower if the analyses of the oxalic acid

metabolites, glycolic acid and glyoxylic acid, were performed parallel to the analyses of oxalic acid, because the likelihood that all parameters are low at the same time due to fluctuations will be reduced.

There have been many problems in the analysis of oxalic acid and many different methods have been used (4, 5). A high degree of reproducibility was found in this study by the method of Zaremski & Hodgkinson (18).

Primary hyperoxaluria in most instances is a serious disease, leading to renal insufficiency, uraemia and death before the age of twenty. According to the present study there obviously are differences in age of onset and the severity of clinical symptoms, indicating different phenotypes of the disease. In case 8 there was an early onset of the disease with severe renal insufficiency, leading to uraemia and death at the age of eight months, while in case 2 the first clinical symptoms were seen at the age of 22 years.

Many therapeutic trials have been performed in primary hyperoxaluria. Pyridoxine has been used in order to increase the transamination of glyoxylic acid to glycine and thus reduce the oxidation to oxalic acid (10). Calcium carbimide, an oxidase inhibitor, has been used to reduce the oxidation of glyoxylic acid to oxalic acid (15). Magnesium oxide (7) has been given to increase the excretion of more soluble magnesium oxalate and high phosphate regimen (12) to reduce the calcium excretion and thus, in both ways, to reduce the formation of calcium oxalate calculi.

In the present study pyridoxine medication was tried in cases 1, 2, 5 and 6 for 2–8 years. A significant reduction in the urinary excretion of oxalic acid was seen during the period of treatment but there was no permanent normalization. In cases 1 and 2, only a slight progress of the clinical symptoms was seen during the treatment, while in cases 5 and 6, the progress was fast leading to renal insufficiency and death in case 6.

By administration orally of magnesium oxide, theoretically more soluble magnesium-oxalate should be excreted instead of calcium oxalate and thus reduce the calculi formation. This therapy is going on in case 2.

In case 6 a renal transplantation was performed but calcinosis due to calcium oxalate crystals appeared in the transplanted kidney after a few months. This indicates that it is little sense in performing renal transplantation (8) as well as

hemodialysis (2) in a systemic metabolic disease like hyperoxaluria.

In conclusion

According to the present study it is a wide diversity in the clinical expression of primary hyperoxaluria, and many cases may be disregarded because of too little knowledge about the disease. In familial cases of nephrolithiasis in childhood which turn out to be negative when analysed for urinary cystine, analysis for oxalic acid, glycolic acid and glyoxylic acid should be performed.

ACKNOWLEDGEMENTS

This study was supported by grants from the Borgström Foundation, University of Uppsala and the Findus Fund for Nutritional Research.

REFERENCES

1. Archer, H. E., Dormer, A. E., Schrowen, E. F. & Watts, R. W. E.: Primary hyperoxaluria. *Lancet* *ii*: 320, 1957.
2. Boquist, L., Lindqvist, B., Östberg, Y. & Steen, L.: Primary oxalosis. *Am J Med* *54*: 673, 1973.
3. Calkins, V. P.: Microdetermination of glycolic and oxalic acids. *Indust Eng Chem Analyt Ed* *15*: 762, 1943.
4. Chanansol, G. & Desgrez, P.: Utilisation de la chromatographie en phase gazeuse pour la détermination quantitative de l'acide oxalique. *J Chromatogr* *48*: 550, 1970.
5. Daniels, R. A., Michels, R., Aisen, P. & Goldstein, G.: Familial hyperoxaluria. *Am J Med* *29*: 820, 1960.
6. Davis, J. S., Klingberg, W. G. & Stowell, R. E.: Nephrolithiasis and nephrocalcinosis with calcium oxalate crystals in kidneys and bones. *J Pediat* *36*: 323, 1950.
7. Dent, C. E. & Stamp, T. C. B.: Treatment of primary hyperoxaluria. *Arch Dis Child* *45*: 735, 1970.
8. Deohar, S. D., Tung, K. S. K., Zühlke, V. & Nakamoto, S.: Renal homotransplantation in a patient with primary familial oxalosis. *Arch Path* *87*: 118, 1969.
9. Gibbs, D. A. & Watts, R. W. E.: The variation of urinary excretion with age. *J Lab Clin Med* *73*: 901, 1969.
10. Gibbs, D. A. & Watts, R. W. E.: The action of pyridoxine in primary hyperoxaluria. *Clin Science* *38*: 277, 1970.
11. Hockaday, T. D. R., Clayton, J. E., Frederick, E. W. & Smith, L. L. H.: Primary hyperoxaluria. *Medicine* *43*: 315, 1964.
12. Howard, J. E., Thomas, W. C., Jr, Mukai, T., Johnston, R. A., Jr & Pascoe, B. J.: The calcification of cartilage by urine, and a suggestion for therapy in patients with certain kinds of calculi. *Tr A Am Physicians* *75*: 301, 1962.
13. Lepoutre, C.: Calculs multiples chez un enfant. Infiltration du parenchyme rénal par de cristaux. *J Urol (Paris)* *20*: 424, 1925.
14. Newns, G. H. & Black, J. A.: A case of calcium oxalate nephrocalcinosis. *Gt Ormond St J* *5*: 40, 1953.
15. Salomons, C. C., Goodman, S. I. & Riley, C. M.: Calcium carbimide in the treatment of primary hyperoxaluria. *New Engl J Med* *276*: 207, 1967.
16. Williams, H. E. & Smith, L. H.: Disorders of oxalate metabolism. *Am J Med* *45*: 715, 1968.
17. Zaremski, P. M. & Hodgkinson, A.: The microdetermination of glyoxylic acid in blood, urine and bacterial extracts. *Biochem J* *96*: 217, 1965.
18. Zaremski, P. M. & Hodgkinson, A.: The fluorimetric determination of oxalic acid in blood and other biological materials. *Biochem J* *96*: 717, 1965.
19. Öigaard, H. & Söderhjelm, L.: Familial oxalosis. *Acta Soc Med Upsal* *62*: 176, 1957.
20. Öigaard, H., Söderhjelm, L., Höglund, N.-J. & Werner, I.: Familial oxalosis. II. *Acta Soc Med Upsal* *68*: 55, 1963.

Received July 7, 1977

Address for reprints:

Gösta Holmgren, M.D.
Department of Pediatrics
University Hospital
S-90185 Umeå
Sweden