

## **P-Wave Analysis in Chronic Obstructive Lung Disease with Pulmonary Hypertension**

B. FURBERG, L. NORDGREN and RITVA TAMMIVAARA-HILTY

*From the Departments of Clinical Physiology (Head: Professor G. Ström) and Pulmonary Diseases (Head: Professor G. Dahlström), University Hospital, Uppsala, Sweden*

### **ABSTRACT**

**In a group of 24 patients with severe chronic obstructive lung disease and varying degrees of pulmonary hypertension, a study was made of the relationship between haemodynamic data and the P wave as recorded both by conventional ECG and by a special recording method. An increased P-wave amplitude was recorded in 33% and 42% of the patients, respectively, with the two methods. None of the 5 patients with marked pulmonary hypertension and an elevated PCV pressure showed an increase of the P-wave amplitude, while all 6 patients with marked pulmonary hypertension but no elevation of the PCV pressure showed an increase of this amplitude on special recording. Changes in configuration of the P wave seem to be related to an increased PCV pressure.**

### **INTRODUCTION**

The aim of this investigation was to study, in a group of patients with advanced chronic obstructive pulmonary disease and varying degrees of pulmonary hypertension, the relationship between haemodynamic data and the P wave recorded both by conventional ECG and by a special method (7) giving high discrimination of the atrial activity.

### **MATERIAL AND METHODS**

The study was performed on 24 patients (18 men and 6 women of ages between 39 and 70 years, mean age 60.8 years) with a 3 to 10-year history of severe chronic obstructive pulmonary disease. From the original material of 25 patients one patient with nodal rhythm was excluded. Thirteen of the patients had had at least one period of respiratory insufficiency that had necessitated breathing assistance by a physiotherapist or treatment with a respirator. The maximal ventilatory capacity at a free frequency ( $MVV_F$ ) varied between 10 and 35% of the predicted value and the forced expiratory volume in

per cent of the obtained vital capacity (FEV%) varied between 18 and 50%. A detailed description of the clinical and the physiological findings are given elsewhere by Brundin & Tammivaara-Hilty (2) and Tammivaara-Hilty (11).

Right heart catheterization with pressure and flow measurements at rest was performed on all patients and corresponding measurements during exercise were made on 22 of the 24 patients. All examinations were carried out at a time when the patients were assessed clinically to be in an optimal state.

Seven of the 24 patients were found on catheterization to have an elevated pulmonary capillary venous (PCV) pressure, either at rest (lowest 13 and highest 23 mmHg) or during exercise (lowest 21 and highest 36 mmHg). The mean pressure in the pulmonary artery (PA) at rest was higher than normal in all patients, moderately increased (18-27 mmHg) in 13 patients and markedly increased (28 mmHg or higher) in 11 patients. According to these limits for the mean PCV and PA pressures, the patients were divided into four groups (see Table I).

Recording of 12-channel ECG (leads I, II, III, aVR, aVL, aVF,  $V_{1-6}$ ) with the conventional amplification (1 mV = 10 mm) and a paper speed of 50 mm/sec, using a direct-writing ECG apparatus (Mingograf 81, Elema Schönander Ltd., Sweden), was done the day after the heart catheterization with the patient at rest in the recumbent position. On the same occasion three bipolar chest leads were recorded. These three leads have a common electrode placed over the sternal angle. The first lead (S1) measures the potential difference between the highest point in the left midaxillary line and the common electrode. The second lead (S2) measures the potential difference between the distal end of the sternal body and the common electrode and the third lead (S3) measures the potential difference between a point over the spinal column at the level of the sternal angle and the common electrode. In this recording a 3-channel differential pre-amplifier with a 10-times higher amplification (0.1 mV = 10 mm) than in a conventional ECG recording was used and the ECG recorded with a Mingograf 81. The paper speed was 100 mm/sec.

Fifty control subjects (age 20-71 years, with no known heart or lung disease) were studied by the special bipolar ECG method.

The amplitude of the P wave in the extremity leads II, III and aVF was measured (to the nearest  $\frac{1}{2}$  mm). The amplitude of P in the lead with the highest P wave

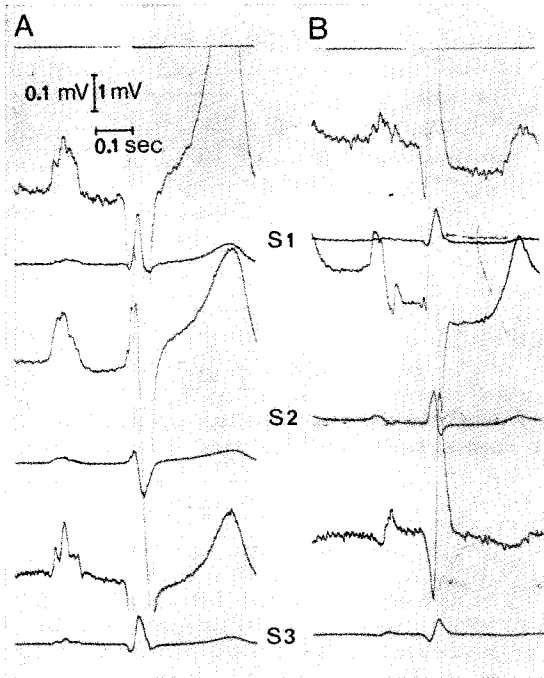


Fig. 1. Examples of special recordings A, normal P wave; B, P wave with "abnormal" configuration.

(usually II) was noted. As a criterion of P pulmonale a P-wave amplitude of  $\geq 2.5$  mm (0.25 mV) in leads II, III or aVF was used.

In lead  $V_1$  the highest positive amplitude (mm) and the duration (sec) of the initial P portion were measured and by multiplication of these values the "P initial force" was obtained (6). The range  $-0.01$  to  $+0.07$  was used as the normal range of "P initial force" as recommended by Morris et al. (6).

In the bipolar chest lead S2 the beginning and end of the P wave were connected by a line and the maximal amplitude in mm over this line was measured. The mean value of three different P-wave amplitudes was noted. The amplitude of P in S2 was  $\leq 23$  mm (0.23 mV) in 49 of the 50 control subjects, and this was accepted as the

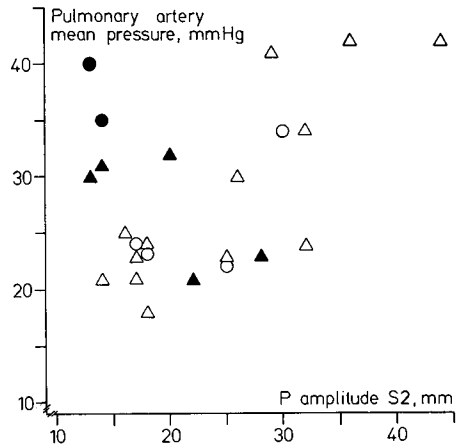


Fig. 2. Relation between P-wave amplitude in special lead S2 and mean pressure in pulmonary artery at rest. Circles represent women, triangles men. Filled symbols indicate patients with an increased PCV pressure.

normal limit. In addition to measurement of the amplitude in S2 the configuration of the P wave was evaluated. The criterion used for an abnormal configuration was a distinctly biphasic P wave with a terminal vector directed posteriorly (see Fig. 1).

The investigator who made the measurements on the ECG recordings had no knowledge of the findings at the other investigations. The first P wave after an extrasystole, if present, was not included.

RESULTS

The results are presented in Table I and Fig. 2.

Eight of the 24 patients (33%) exhibited P pulmonale in the conventional ECG recording, while 10 (42%) showed an increased P-wave amplitude in the special recording. Seven of the 24 patients had an elevated PCV pressure. Of 11 patients with marked pulmonary hypertension, 5 also had an elevated PCV pressure. None of

Table I. Relations between pressures in the lesser circulation and the ECG findings

Group	Mean PA pressure	Mean PCV pressure	No. of patients	Conventional ECG		Special ECG recording	
				P pulmonale	Abnormal "P initial force"	Abnormal P configuration	P amplitude $\geq 24$ mm in S2
A	Markedly increased	Increased	5	0/5	1/5	4/5	0/5
B	Markedly increased	Not increased	6	5/6	2/6	0/6	6/6
C	Moderately increased	Increased	2	1/2	0/2	1/2	1/2
D	Moderately increased	Not increased	11	2/11	0/11	1/11	3/11
			24	8/24	3/24	6/24	10/24

these 5 showed P pulmonale or an increased P amplitude in the special ECG recording, while all 6 patients with marked pulmonary hypertension without elevation of the PCV pressure had a high P-wave amplitude in the special recording. Five of the 7 patients with a raised PCV pressure showed a P wave with an abnormal configuration—biphasic with a terminal vector directed posteriorly—while this change in configuration was seen in only 1 of 17 patients with a normal PCV pressure.

## DISCUSSION

“P pulmonale”, with high, pointed P waves in lead II, was described 1935 by Winternitz (13) in chronic pulmonary disease. Later investigations which have been reviewed by Thomas & Dejong (12), have shown a considerable variation (5–85%) in the occurrence of P pulmonale in this disease.

Reynolds (9) states that with direct leads from the atria the maximal amplitude of P in control cases is influenced by both the right and the left atrium. He found the asynchronism between the atria to be on the average 2.8 csec. In patients with congenital heart disease and high P waves, only a slight increase of the asynchronism between the atria (3.3 csec) was found on recording from the right atrium. In these patients, also, the deflexion thus began in the left atrium before the deflexion in the right atrium had reached its maximum. In patients with mitral stenosis the asynchronism between the atria was 5.1 csec, which meant that the deflexion in the right atrium had passed its maximum before the deflexion in the left atrium had begun.

During the last few years reports have been made on findings of a raised end-diastolic pressure in the left ventricle in patients with chronic obstructive pulmonary disease (4, 8). Left ventricular hypertrophy has been found at autopsy studies in chronic obstructive lung disease (3, 5).

Morris et al. (6) found a significant correlation between the pressure gradient over the pulmonary arterial ostium and the “P initial force” in patients with pulmonary valvular stenosis. Of the 24 patients in our study, only three showed an elevated “P initial force”. These three all belonged

to the group with a pronounced increase of the mean pressure in the pulmonary artery, and one of them also had a raised PCV pressure. The “P initial force” thus does not seem to be a very sensitive measure of pulmonary hypertension in chronic obstructive lung disease.

Sano et al. (10) found, in differential vector cardiography, that with enlargement of the right atrium the maximal vector of the P loop showed an antero-inferior direction, while with enlargement of the left atrium the terminal vector of the loop was oriented postero-inferiorly and to the left. This is the reason that we chose to study the P amplitude in the bipolar special lead S2, and in the presence of a biphasic P wave the terminal vector of the P wave in S3. One particular advantage of the special recording over the conventional ECG is that it allows a more reliable assessment of the P-wave configuration.

Our results indicate that patients with chronic obstructive pulmonary disease and marked pulmonary hypertension with a raised PCV pressure have a lower P-wave amplitude than corresponding patients without a PCV pressure elevation. A possible explanation for this is an increased asynchronism between the atria in patients with an elevated PCV pressure.

## ACKNOWLEDGEMENT

This study was financially supported by the Swedish National Association against Heart and Chest Diseases.

## REFERENCES

1. Baum, G. L., Schwartz, A., Llamas R. & Castillo C.: Left ventricular function in chronic obstructive lung disease. *New Eng J Med* 285: 361, 1971.
2. Brundin, A. & Tammivaara-Hilty, R.: Clinical and physiological follow-up of severe chronic obstructive lung disease. *Scand J Resp Dis Suppl* 79, 1972.
3. Fluck, D. C., Chandrasekar, R. G. & Gardner, F. W.: Left ventricular hypertrophy in chronic bronchitis. *Brit Heart J* 28: 92, 1966.
4. Lockhart, A., Tzareva, M., Nader, F., Leblanc, P., Schrijen, F. & Sadoul, P.: Elevated pulmonary wedge pressure at rest and during exercise in chronic bronchitis: fact or fancy. *Clin Sci* 37: 503, 1969.
5. Michelsen, N.: Bilateral ventricular hypertrophy due to chronic pulmonary disease. *Dis Chest* 38: 435, 1960.

6. Morris, J., Estes, H., Whalen, R., Thompson, H. & McIntosh, H.: P-wave analysis in valvular heart disease. *Circulation* 29: 242, 1964.
7. Nordgren, L.: A new method to study atrial activity—intended for clinical use. *Acta Soc Med Upsal* 74: 186, 1969.
8. Rao, S., Cohn, K. E., Eldridge, F. L. & Hancock, E. W.: Left ventricular failure secondary to chronic pulmonary disease. *Amer J Med* 45: 229, 1968.
9. Reynolds, G.: The atrial electrogram in mitral stenosis. *Brit Heart J* 15: 250, 1953.
10. Sano, T., Hellerstein, H. & Vayda, E.: P vector loop in health and disease as studied by the technique of electrical dissection of the vectorcardiogram. *Amer Heart J* 53: 854, 1957.
11. Tammivaara-Hilty, R.: Central haemodynamics at rest and during exercise in severe chronic obstructive lung disease. *Upsala J Med Sci* 77: 149, 1972.
12. Thomas, P. & Dejong, D.: The P wave in the electrocardiogram in the diagnosis of heart disease. *Brit Heart J* 16: 241, 1954.
13. Winternitz, M.: Zur Pathologie des menschlichen Vorhofelektrokardiogramms. *Med Klin* 48: 1575, 1935.

*Received June 16, 1972*

Address for reprints:

Ritva Tammivaara-Hilty, M.D.  
Department of Clinical Physiology  
University Hospital  
S-750 14 Uppsala 14  
Sweden